

# Fanconi's anaemia and anaesthesia

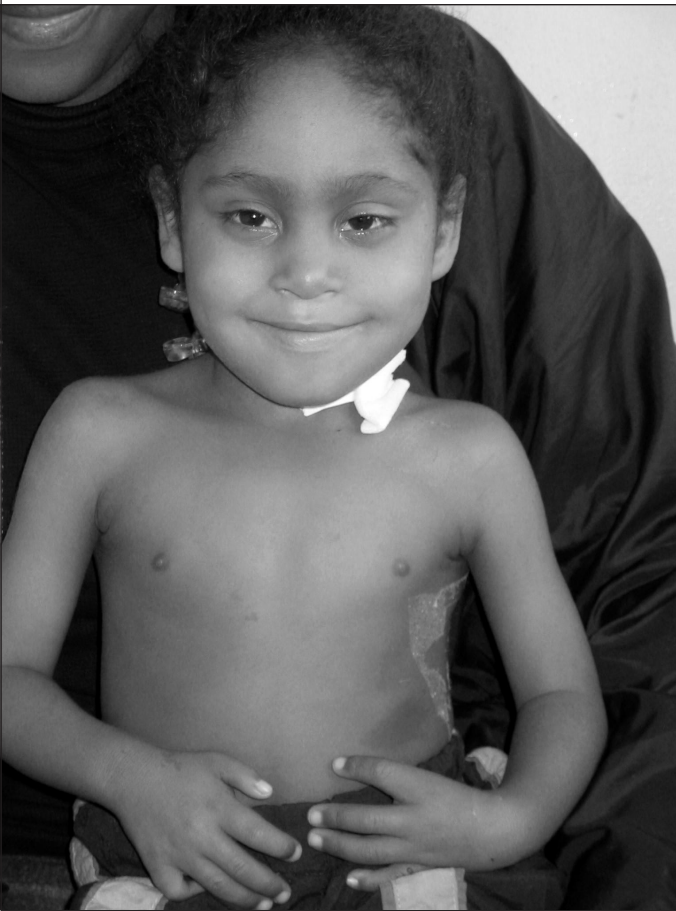SJB Johnston, AT Bösenberg

Department of Anaesthesia, Faculty of Health Sciences, University Cape Town, South Africa

## Case presentation

A 5-year old girl was referred for ligation of her patent ductus arteriosus. This was her first admission to hospital. According to her mother she had been previously healthy and had reached all her milestones at the appropriate ages. She was small in stature and weighed 13kg placing her on the 3rd centile of her physical growth chart. Her most striking physical feature was the abnormal appearance of her upper limbs

**Figure 1:** Five year old girl with upper limb abnormalities (shortened radii, absent left thumb and hypoplastic right thumb), almond shaped eyes and café-au-lait spots visible on her trunk just above her left hand.

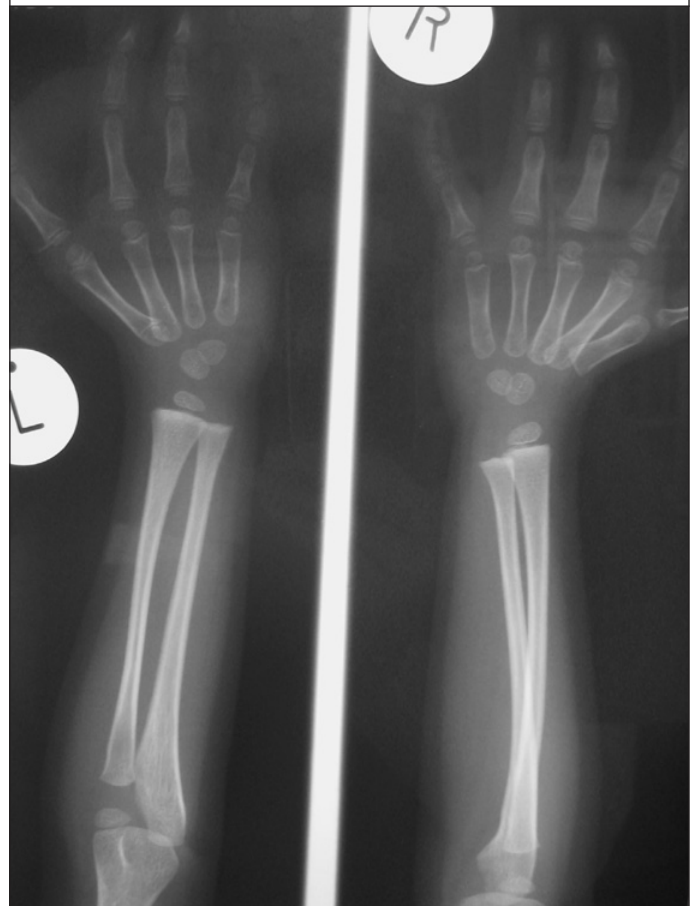

– she had bilateral radial hypoplasia with an absent left thumb and hypoplastic right thumb (Fig 1 & 2). She also had almond shaped eyes, and café-au-lait spots were visible on her trunk. There was no evidence of bruising or petechiae.

She had a mild scoliosis that was confirmed on chest x-ray and the presence of a hemi-vertebra at T4 level was noted (fig 3). Further preoperative investigations included an ultrasound of her abdomen that demonstrated a functional right kidney in the epigastrium and a normally sited left kidney. Her haemoglobin was 9.5g/dl and platelet count 96 000 $\mu$ L. Her urea and electrolytes were within normal limits.

She has a 7-year old sister with similar upper limb abnormalities who had been diagnosed with Fanconi's Anaemia. No other family members were affected. A provisional diag-

**Figure 2:** Radiograph of her forearms showing absent left thumb and radial hypoplasia.

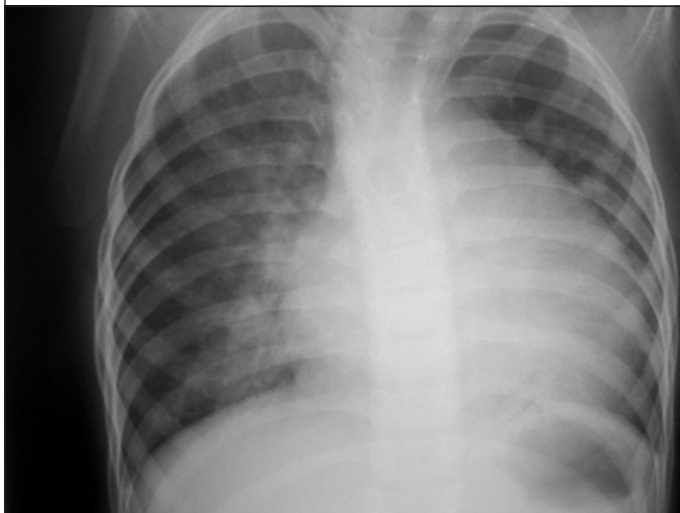


## Correspondence:

Professor A Bösenberg

email: bosie@cormack.uct.co.za

Figure 3: Chest x-ray showing hemi vertebra at T4 as well as scoliosis



nosis of Fanconi's Anaemia (FA) was made but confirmatory chromosome fragility tests are still outstanding.

### Fanconi's anaemia

Fanconi's Anaemia (FA) is an autosomal recessive disorder, characterised by progressive pancytopenia, associated congenital abnormalities and a high risk of developing leukaemia. It was first described by Guido Fanconi, a Swiss paediatrician, in 1927<sup>2</sup>, who documented a form of aplastic anaemia present in 3 brothers with short stature, hypogonadism and abnormal skin pigmentation.

FA should not be confused with Fanconi Syndrome, which is also an inherited disorder, associated with proximal renal tubular dysfunction (glycosuria, phosphaturia, aminoaciduria and bicarbonate wasting) and often cystinosis.<sup>1</sup> TAR (thrombocytopenia-absent radii) syndrome is another autosomal recessive disorder with similar features, which is a separate entity.

The reported incidence of FA is 3 per million births. The incidence of the heterozygote type varies, and is reported to be 1 in 300 in the US and Europe<sup>2</sup> as well as in the black population in South Africa.<sup>2</sup> However, it is much more frequent amongst Afrikaners and Ashkenazi Jews with a heterozygote frequency of 1 in 83 and 1 in 89 respectively.<sup>2</sup>

Mutations in at least 7 different genes have been identified. These mutations cause chromosomal instability, especially in the presence of alkylating agents, which results in a disruption of DNA repair, abnormal regulation of apoptosis and defective haemopoiesis. This chromosomal instability forms the basis of a diagnostic fragility test.

### Clinical manifestations

Approximately a third of these children may have no physical abnormalities aside from their haematological involvement. The remainder however, may present with a wide heterogeneity of clinical manifestations.

Skeletal abnormalities are the most common (70%) and include radial ray defects (hypoplasia of the thumb and or radius), rib and vertebral defects (Fig 3) and congenital hip dislocation. Small or absent thumbs are considered a hallmark of the syndrome. These children are generally of short stature, which in some cases may be related to superimposed

endocrinopathies such as growth hormone deficiency and hypothyroidism.

Renal and urinary tract abnormalities are present in a third of patients. These range from renal aplasia or hypoplasia; horseshoe or ectopic kidneys, to double ureters. Hypogonadism is common and often associated with cryptorchidism.

CNS manifestations are also varied and 15% are developmentally delayed - most likely on the basis of microcephaly or other sensory deficits. Conductive deafness has been noted in up to 10% of patients. Ocular involvement is present in just under half of the patients, and may include microphthalmia, strabismus and typical almond-shaped eyes. Skin manifestations include café-au-lait spots and areas of hyper- or hypopigmentation.

Less common manifestations include congenital cardiac abnormalities (PDA, VSD, pulmonary stenosis, aortic stenosis, coarctation), gastrointestinal (atresias, imperforate anus, tracheo-oesophageal fistula) and central nervous system (hydrocephalus, neural tube defects) abnormalities.

### Haematological manifestations

FA is the commonest type of inherited bone marrow failure syndrome. These patients have a normal blood count at birth (unlike the TAR (thrombocytopenia-absent radii) syndrome which has thrombocytopenia at birth). A macrocytosis is often first detected, followed by a decrease in platelet count and then neutropenia. Pancytopenia usually presents between 5-10 years with a median of 7 years.<sup>2</sup> Complications as a result of this pancytopenia include recurrent or intractable haemorrhage and infections.

There is a markedly increased risk of aplastic anaemia and acute myeloid leukaemia in these children. In a study of the International Fanconi Anaemia Registry of 388 patients they calculated that by the age of 40 the risk of developing haematological abnormalities was 98% and the risk of death from haematological causes was 81%.<sup>6</sup> In those patients who survive to early adulthood there is a much higher risk of solid tumours, notably hepatic tumours (possibly related to androgen therapy) and squamous carcinomas of the oesophagus, oropharynx and vulva.

When the clinical diagnosis is suspected, it can be confirmed with chromosome fragility (breakage) studies. Further investigations should be performed to exclude associated abnormalities. These include a full haematological assessment (including bone marrow biopsy for possible bone marrow transplantation), renal ultrasound, hearing tests and cardiac evaluation if a murmur is detected. An endocrine assessment is necessary to exclude other causes of growth retardation. The family should be referred to a geneticist so that the siblings can be investigated.

Initially the haematological management is confined to regular monitoring. Once the patients become symptomatic, oral androgens enhance erythropoietin production and increase bone marrow cellularity. Cytokine therapy can improve haemopoiesis, either in conjunction with androgens or where androgens have failed. The treatment of choice is bone marrow transplantation, which may be curative. Future therapies may well include gene therapy<sup>3</sup> and as the corrected FA cells are likely to have a selective advantage over the defective ones, this will eliminate the need for bone marrow transplantation.

## SYNDROMIC VIGNETTES IN ANAESTHESIA

---

### Anaesthetic considerations

Children with FA may have many congenital abnormalities which need to be excluded, or their management optimised, prior to anaesthesia. They present for plastic or reconstructive surgery, cardiac surgery or urological procedures related to these congenital abnormalities, or may need to undergo incidental surgery. It is essential that the haematocrit and platelet count are evaluated before surgery.<sup>1</sup>

The abnormal upper limb anatomy influences the conduct of the anaesthetic. IV lines and non-invasive blood pressure cuff are probably best on the lower limbs. As regards invasive monitoring, the placement of radial arterial lines may be difficult and in some cases hazardous and therefore best avoided.<sup>1</sup> Similarly, regional blockade of the upper limb should be used with caution. Aseptic technique for any invasive procedure is especially important when neutropaenia is present.

### References

1. *Anaesthesia for genetic, metabolic and dysmorphic syndromes in children.* Baum V, O'Flaherty J eds, Lippincott Williams & Wilkins USA 1999 pp 108
2. Tischowitz MD, Hodgson SV. *Fanconi anaemia.* *J Med Genet* 2003;40:1-10
3. Kannan K, Dennison D, Nusrat N. *Fanconi's Anaemia.* *Br J Haemat* 2003; 122:521
4. Venkitaraman AR. *A Growing Network of Cancer – Susceptibility Genes.* *N Engl J Med* 2003, 348;19:1917-9
5. Naidoo JA, Hesselring P. *Blood disorders. Chapter 18, pp 406-7, Paediatrics and Child Health.* Coovadia HM, Loening WEK eds, Oxford University Press, Cape Town 1992.
6. Butterini A, Gale RP, Verlander PC, Adler-Brecher B, Gillio AP, Auerbach AD. *Hematological abnormalities in Fanconi anemia: an International Fanconi Anemia Registry study.* *Blood* 1994; 84:1650-5
7. Alter BP. *Fanconi's anemia: current concepts.* *Am J Pediatr Hematol Oncol* 1992; 14:170-176.

