

Case Report

MANAGEMENT OF PELVIC FRACTURES IN DOG

SHARMA, A.K*, SHIVENDRA KUMAR AND L.L.DASS

Dept. of Surgery and Radiology, College of Veterinary Science and Animal Husbandry,
Birsra Agricultural University, Kanke, Ranchi-834006

*Corresponding author: Email: arsham10@rediffmail.com; Tel: +916512450883

INTRODUCTION

Pelvic fractures are common sequelae of major traumatic injury of dogs and cat which, comprise of at least 25% of all fractures in veterinary practice (Piermattei *et al.*, 2006). Fracture of ilium, the most common fracture seen in the pelvis account for 46% of all pelvic fracture (Henry, 1985; De Camp, 2005). Whereas, acetabular fracture comprises 12 % of pelvic fractures in dogs (De Camp, 2005). In smaller dogs, most of the pelvic fractures recover without surgery. But immediate surgery is required within 72 hours if the fracture is unstable (Harasen, 2007). We hereby report the successful surgical management of unstable fracture of ilium and ischium of pelvis in a Spitz dog.

KEY WORDS: Dog, dynamic compression plate, pelvic fracture

HISTORY AND OBSERVATIONS

A Spitz bitch of 1^{1/2} years and weighing 8 kg was brought to the Department of Surgery and Radiology, Ranchi Veterinary College, Ranchi, which had suffered a severe accidental fall from a height of second floor of building over the roof of a running car 2 days prior to the presentation in the clinics. As a sequel to this, the dog evinced inability to bear weight on left hind limb. The affected limb appeared to be shorter as compared to the contralateral limb (fig 1). Abrasion and contusion could be noticed on the caudal aspect of tuber ischii. A crepitating sound was audible during manipulation of pelvis which was suggestive of unstable fracture. Though the animal had inappetance and depression, but had normal defaecation and urination. Based on clinical examination, radiography of pelvic bone

in dorsoventral, lateral and ventrodorsal view was suggested, which revealed the complete fracture of ilium and ischium but the acetabulum was intact. The caudal portion of ilium along with acetabulum was displaced medially and cranially towards the cranial portion of ilium (fig 2).

TREATMENT AND DISCUSSION

Because of unstable pelvic fracture, it was decided to proceed for surgical management. The patient was stabilized with administration of Dextrose normal saline 200 ml intravenously and Ceftriaxone at 250 mg intramuscularly, preoperatively. The affected limb was prepared aseptically from dorsal mid line to mid tibia and from 10 cm cranial to iliac prominence to the base of the tail caudally.

Sharma et al: Management of pelvic fracture in a Spitz dog

The bitch was anaesthetized with xylazine Hcl at 1mg/kg body weight (b.wt) and ketamine Hcl at 5 mg/kg b.wt

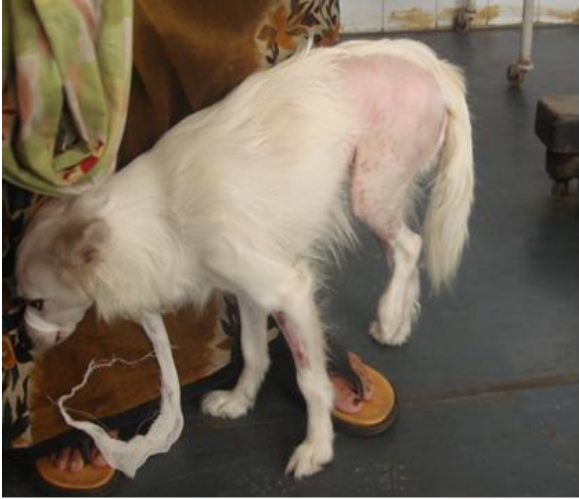

Figure 1. Animal before operation with inability to bear weight and appear to be shorten.

ilium and ischium and cranial displacement of fractured part.

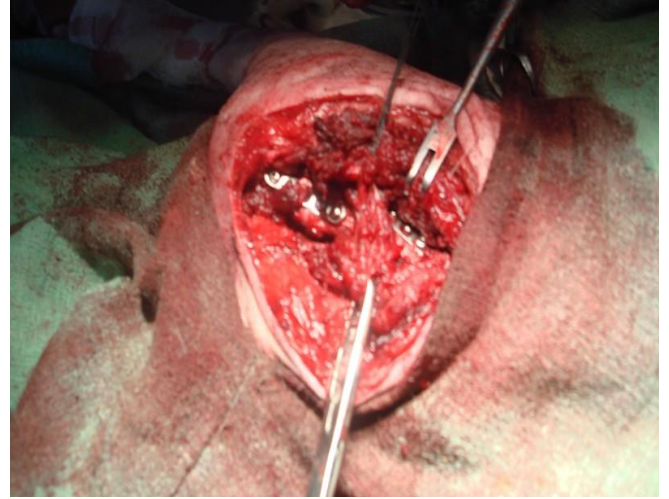


Figure 3. Composite fixation of ilium and ischium fracture with dynamic compression plate (DCP).

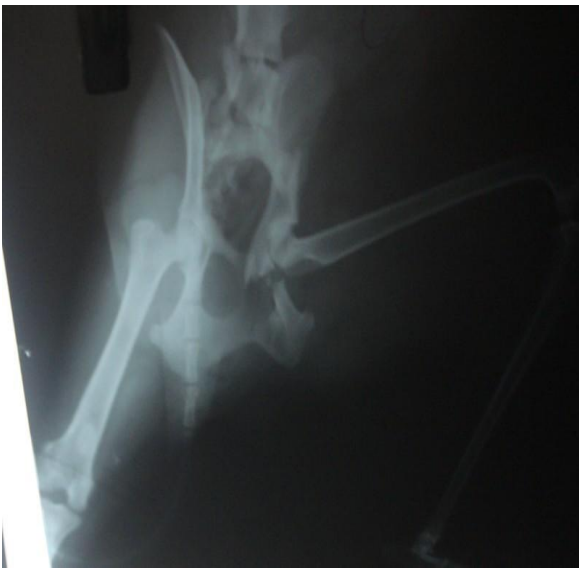

Figure 2. Ventrodorsal radiograph of pelvis demonstrates unilateral fracture of

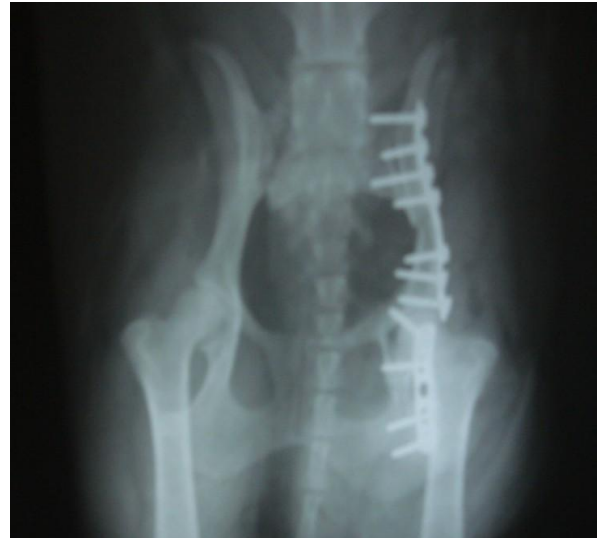

Figure 4. Radiograph (V.D. view) of pelvis after fixation.

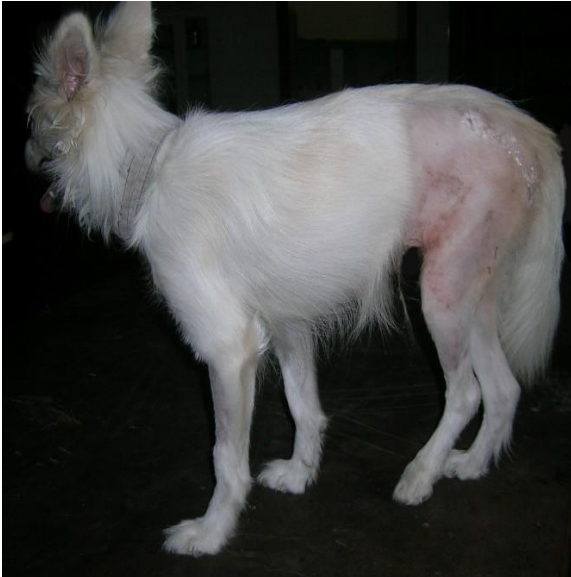

Figure 5. Animal 20 days post-operatively with weight bearing.

intramuscularly after being premedicated with atropine sulphate at 0.04mg/kg b.wt subcutaneously. The maintenance of anaesthesia was carried out with ketamine hydrochloride. The dog was positioned in lateral recumbency and incision was made from the cranial extent of the iliac crest to adjacent to the caudal border of the greater trochanter concurrent with the lateral approaches to ilium as described by Johnson and Dunning (2007). Contrary to this pelvis is also approachable through dorsal midline incision in sternal position as described by Olmstead (1995). The ilial wing was approached by incising and reflecting the tensor fasciae lata and middle gluteal muscle whereas, ischium was exposed by reflecting the biceps femoris muscle caudally to expose the sciatic nerve. The dynamic compression plate was attached to the caudal segment first with bone screw. The alignment

was made with cranial segment by using bone elevator and retracting forceps. After alignment the dynamic compression plate of 2.5 mm 8 holes was clamped to the cranial segment of the ilium to obtain lateralization of the caudal ilial segment and to maintain reduction. The plate was fixed with the application of 4 screws in the cranial segment and three screws in the caudal segment (fig 3-4). A similar principle was also applied for the immobilization of ischial fragment by dynamic compression plate of 2.5mm 5 holes. The incisional wound was sutured routinely. Post-operatively, intramuscular injection of Ceftriaxone at 250 mg for 7 days and Meloxicam at 1mg/4 kg bodyweight was administered for 3 days. Further, the animal was administered inj. of Vitamin – D at 2 ml once in week for 3 weeks and osteocalcium syrup orally at 1tsf twice daily for 1 month and B- complex was administered at 0.5 mg/kg b.wt for 5 days. The cutaneous sutures were removed on 12th post-operative day. The bitch recovered uneventfully (fig 5).

Pelvic fractures are always result of major trauma, impact from side may drive the femoral head into acetabulum, resulting in acetabulum fracture with associated fracture of adjacent portion of ilium and pubis (Olmstead, 1998). The present fracture was also caused by impact from one side as judge by contusion and abrasion caudal to the tuber ischi which, resulted in fracture of ilium and ischium but acetabulum was intact. The most common criteria for recommending surgical repair of pelvic fracture include the following: displaced acetabular fracture (cranial 2/3rd of acetabulum) greater than 1/3 narrowing of the pelvic canal diameter by fracture fragments, neurologic impairment (intractable pain due to fracture),

ipsilateral fracture of ilium, ischium and pubis (unstable hip joint) or contralateral orthopaedic injuries requiring early weight bearing on the pelvic fracture side (Piermattei *et al.*, 2006). The pain is well managed by cage rest in cases with minimum displaced fracture and fracture outside the cranial 2/3rd of the acetabulum (Fossum, 2007). The present case was managed by surgical operation because of unstable pelvic fracture. The shortening of limb may be due to cranial displacement of acetabulum along with fractured ilium and ischium. The surgical operation was performed within 72 hours of incidence which gives better immobilization otherwise fibrous healing and muscle rigidity will make surgical reduction and repair increasingly difficult (Piermattei *et al.*, 2006). Bone plate repair is the most common and successful means of surgical management of pelvic fractures (Harasen, 2007).

REFERENCES

- DECAMP, C.E. (2005) Fractures of the pelvis. In: Johnson, A.L. and Houlton, J.E.F., Vannini, R. eds. AO Principles of fracture management in the dog and cat, New York: Thieme, pp. 161-199.
- FOSSUM, T.W. (2007) Pelvic fractures. In: Fossum, T.W., 3rd edn. Small Animal Surgery. Mosby, St. Louis, Missouri, pp.1087-88.
- HARASEN, G. (2007) Pelvic fractures. *Can. Vet. J.*, **48(4)**: 427-28.
- HENRY, W. B. (1985) A method of bone plating for repairing of iliac and acetabular fractures. *Compend.*

Contin. Educ. Pract. Vet., **7**: 924-938.

- JOHNSON, A.L. AND DUNNING, D. (2005) Atlas of orthopaedic surgical procedures of the dog and cat. Elsevier Saunders, St. Louis, Missouri, pp. 176.
- OLMSTEAD, M.L. (1995) Fractures of the bones of the hind limb. In : Olmstead, M.L., ed. Small Animal Orthopaedics. Mosby, St. Louis, Missouri, pp.221-222.
- OLMSTEAD, M.L. (1998) The pelvis and sacroiliac joint. In: Coughlan Miller A, eds. Manual of Small Animal Fracture Repair and Management. Cheltenham: *Br. Small Anim. Vet. Assoc.*, pp. 217-219.
- PIERMATTEI, D. L., FLO, G.L. AND DECAMP, C.E. (2006) Hand book of Small Animal orthopaedics and fracture repair, 4th ed. St. Louis, Saunders, pp. 433-60.