

# Clinical Parameters and Challenges of Managing Cervicofacial Necrotizing Fasciitis in a Sub-Saharan Tertiary Hospital

Adeola A Olusanya, Olalere O Gbolahan, Timothy O Aladelusi, Victor I Akinmoladun, Juwon T Arotiba

Department of Oral and Maxillofacial Surgery, University College Hospital, Ibadan, Nigeria

## ABSTRACT

**Introduction:** Necrotizing fasciitis is a severe soft tissue infection. In our environment, patients presenting with this infection are usually financially incapacitated and, therefore, their management can be challenging. This paper aimed to document the pattern and challenges encountered in the management of cervicofacial necrotizing fasciitis (CNF) in the University College Hospital, Ibadan. **Materials and Methods:** Information such as biodata, site of infection, systemic conditions, widest span of defect, management provided, hospital stay, and outcome of management was prospectively collected on all patients with CNF who presented at the Department of Oral and Maxillofacial Surgery between January 2007 and December 2013. The patients were managed according to a devised protocol of antibiotic therapy, serial debridement and honey dressings. **Results:** Twenty-four cases of CNF were seen. There were 9 males and 15 females while 70.9% of the patients belonged to the low socioeconomic class. The mean span of wound defect was 12.2 ( $\pm 8.844$ ) cm. The mean hospital stay was 27.8 ( $\pm 23.1$ ) days, and scar formation was the most common complication encountered. **Conclusion:** Our study represents the largest series of CNF from a Nigerian health facility presently. The management of necrotizing fasciitis in the maxillofacial region poses a significant challenge to both the surgeon and the patient. However, the mortality rate of CNF in our center appears comparatively low.

**KEYWORDS:** Cervicofacial necrotizing fasciitis, management, outcome

## INTRODUCTION

Necrotizing fasciitis is a potentially fatal, rapidly progressive soft tissue infection that involves fascial planes, initially sparing overlying skin and underlying muscle.<sup>[1-6]</sup> Necrotizing fasciitis has been referred to by many different names such as hospital gangrene, flesh eating disease, streptococcal hemolytic gangrene, synergistic necrotizing cellulitis, and Fournier's gangrene when it involved the perineum.<sup>[1,3,7,8]</sup> It was described by Joseph Jones in 1871 during the American Civil war but was first described as necrotizing fasciitis in 1952 by B. Wilson.<sup>[1,3,7-11]</sup> When this condition occurs in the head and neck region, it is referred to as

### Address for correspondence:

Dr. Adeola A Olusanya,  
Department of Oral and Maxillofacial Surgery, University College  
Hospital, Ibadan, Nigeria.  
E-mail: defamyl@yahoo.com

### Access this article online

#### Quick Response Code:



Website: [www.nigerianjsurg.com](http://www.nigerianjsurg.com)

DOI:  
10.4103/1117-6806.162572

cervicofacial necrotizing fasciitis (CNF). CNF is an uncommon infection and majority of cases are sequel to odontogenic infections.<sup>[1,10]</sup>

Early recognition with prompt intervention is paramount to the management of CNF to prevent serious morbidity or mortality.<sup>[1,2]</sup> Its management involves patient resuscitation, antibiotic therapy, removal of etiological factor (where identified), extensive serial surgical debridement, and subsequent reconstruction.<sup>[1]</sup>

Previous reports of this infection in socioeconomically challenged society like ours, are retrospective in nature and details such as the extent of wound defect, whether management was done on in-patient or out-patient basis, duration of hospital admission and the nature of complications encountered and not just the mortality rate are lacking.<sup>[11,12]</sup> This study aimed at prospectively documenting the presentation, management, challenges, and outcome of management of CNF in our institution.

## MATERIALS AND METHODS

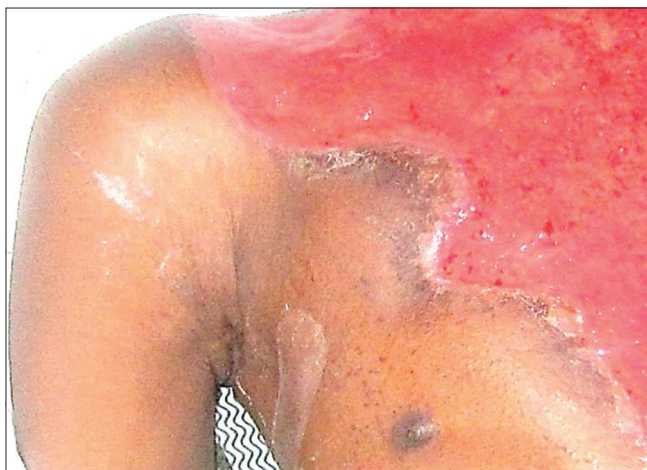Information on age, gender, socioeconomic status, duration of symptoms before presentation, background systemic condition, site of infection, etiology of infection, causative organism (s), antibiotic therapy, span of defect, duration of hospital stay, days to achieve wound closure and complications was collated for all patients who presented at the Department of Oral and

Maxillofacial Surgery in the University College Hospital, Ibadan, with CNF from January 2007 to December 2013.

The socioeconomic status was categorized into high, intermediate, and low according to the classification proposed by Oyedeji.<sup>[13]</sup>

At presentation, all patients were rehydrated with intravenous fluids and given intravenous ceftriaxone (15 g/kg) and metronidazole (7.5 g/kg) after swabs were taken for microscopy, culture, and sensitivity (MCS). Where indicated by the result of MCS, Gentamicin was added to the antibiotic regimen. Antibiotics were given until systemic manifestations of the infection were resolved, and there was no evidence of disease progression. Under local anesthesia, incision and drainage with subsequent serial surgical debridement were commenced, and the wound was copiously irrigated with normal saline and metronidazole and dressed with dilute honey gauze dressing. The first sets of dressings were done twice daily until the wound was devoid of devitalized tissue, and a bed of pinkish granulation tissue covered most of the wound. The frequency of the dressing was subsequently changed to once daily and continued as such till granulation tissue had filled the entire wound defect and evidence of neo-epithelization could be seen at the margins of the defect as shown in Figure 1. This neo-epithelization marked the commencement of wound contraction. At this stage, the widest span of the wound defect was measured with a flexible tape rule and wound biopsy was done to exclude  $\beta$ -hemolytic streptococcus colonization of the wound in preparation for skin grafting otherwise the wound was allowed to contract in cases where patient was financially incapacitated to afford skin grafting procedure.

Patients were also screened for background compromising systemic conditions which were attended to when present in conjunction with appropriate specialties within our hospital. Other supportive therapy including adequate nutritional build up was also carried out for the patients.



**Figure 1:** Wound edges become light pink in color and start to slope inwards toward the wound

Data were analyzed, and results were presented in frequency charts.

## RESULTS

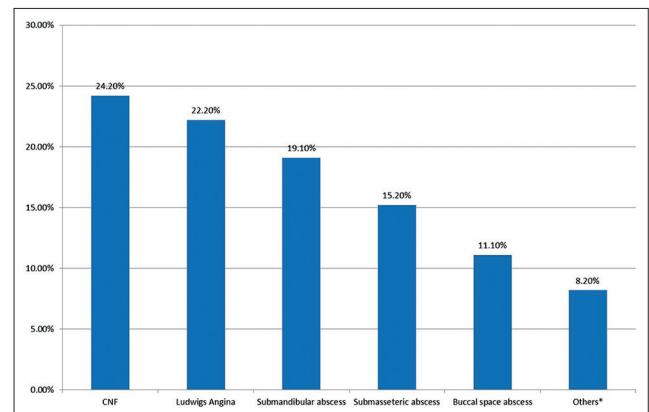
During study period, 12,116 patients attended the maxillofacial clinic, 99 (0.8%) were cases of fascial space infections. CNF was the most common and accounted for 24 (24.2%) cases [Figure 2]. Nine (37.5%) were males and 15 (62.5%) were females with a male to female ratio of 1:1.7. Mean age of the patients was 42.8 ( $\pm 22.444$ ) years while the mean period before presentation was 13.3 ( $\pm 5.531$ ) days as shown in Table 1. Majority of our patients belonged to the low socioeconomic class which accounted for 70.9% of the patients [Table 2]. Figure 3 shows some cases in this study illustrating the site distribution. The submandibulocervical region was the most common site of affection [Figure 3, case 1] with 50.0% and odontogenic infection was the most common etiology while compromising background condition was found in 45.8% [Table 1]. The mean span of the wound defect was 12.2 ( $\pm 8.844$ ) with a median of 10.4 cm and the mean period for wound contraction was 34.4 ( $\pm 34.5$ ) with a median of 19 days [Table 1], giving a rate of 0.5 cm/day. Only one patient was skin grafted, and two patients were managed on out-patient basis. The mean hospital stay was 27.8 ( $\pm 23.1$ ) days [Table 1].

Majority of the complications encountered in our study were scar formation which was functionally limiting in 6 (25.0%) cases while septicemia and death occurred in 2 (8.3%) cases [Table 1].

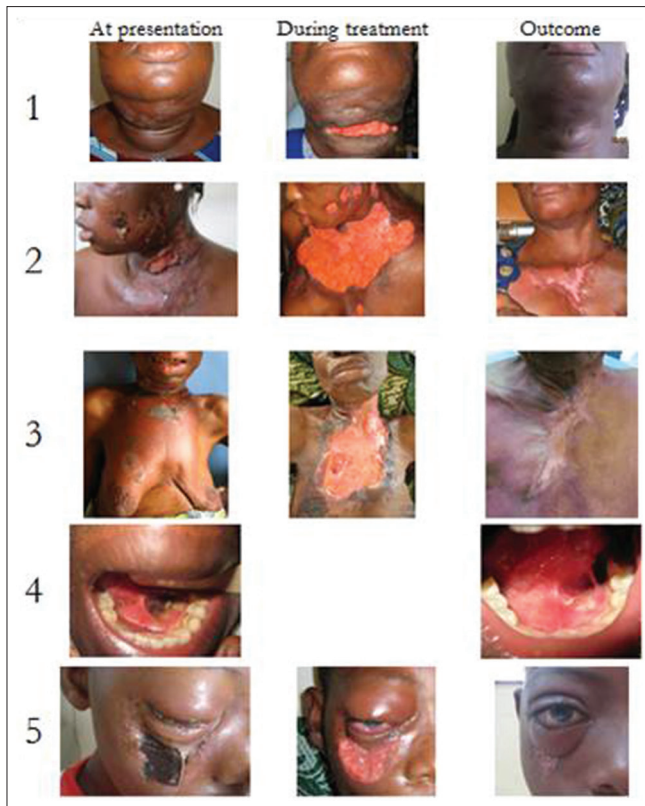Forty-six isolates were obtained from 22 cases, streptococcus pyogenes was the most common isolate, and it occurred solely in 4 cases [Figure 4]. Two cases showed no bacterial growth.

## DISCUSSION

Necrotizing fasciitis can involve any region of the human body. It is more common in the extremities, trunk and perineum but



**Figure 2:** Distribution of cervicofacial infections. \*Others 3 cases of submental abscesses, 2 cases each of canine space and 1 case each of palatal, temporal, and panfacial abscesses

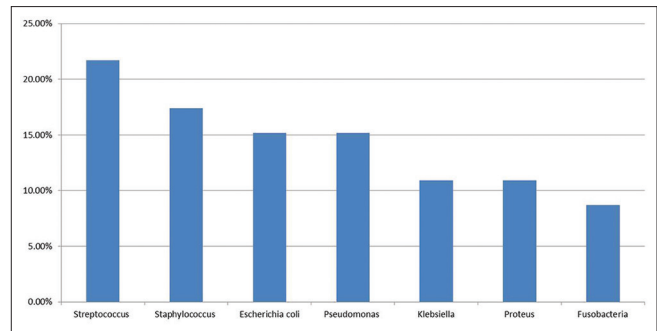


**Figure 3:** Pictures of some of the cases in this study

less common in the maxillofacial region possibly due to the rich blood supply to this region.<sup>[3,7,8,10]</sup> Necrotizing fasciitis involving the mucosal lining appears to be very rare. In fact, CNF was described as an infection that spares mucous membrane in previous literature.<sup>[11]</sup> However, three cases in our study occurred intra-orally with involvement of mucous membrane [Table 1] and the one that involved the floor of the mouth is shown as case 4 of Figure 3.

The pathomechanism of CNF includes infection of the subcutaneous or submucous plane with thrombosis of blood vessels and consequent ischemic necrosis of tissues in the fascial plane initially sparing the skin and underlying muscles.<sup>[2,3,7,10,14]</sup> A high level of suspicion is required for its diagnosis as the clinical presentation at the early stage is often nonspecific.<sup>[7,9,10]</sup> Clinically, the affected region initially becomes diffusely swollen with ill-defined boundaries, erythematous with or without blister formation and exquisitely painful and tender with or without crepitus.<sup>[2,3,7]</sup>

The clinical incidence of CNF among patients seen at our center was not up to 1% at an average of 4 cases/year though higher than the 5 cases over a period of 5 years reported by Mastronikolis *et al.* but similar to the report of Shenoy and Bali.<sup>[1,3]</sup> Local literature suggests an increase in clinical incidence at an annual rate of 0.4 cases in 2001, 0.5 cases in 2002 and 3 cases in 2007.<sup>[11,12,15]</sup> This gradual increase is also reflected in this present study.



**Figure 4:** Isolated micro-organisms

**Table 1: Summary of results**

	Values (%)
Gender	
Males	9 (37.5)
Females	15 (62.5)
Socioeconomic status	
High	1 (4.2)
Intermediate	6 (25.0)
Low	17 (70.8)
Background systemic condition	
None	13 (54.2)
Diabetes mellitus	4 (16.7)
Malnutrition	3 (12.5)
Others <sup>†</sup>	4 (16.7)
Manner of presentation	
Swelling lone	6 (25.0)
Swelling with dusky skin <sup>†</sup>	5 (20.8)
Swelling with intra-oral ulceration	3 (12.5)
Swelling with extra-oral ulceration	10 (41.7)
Site	
Submandibular	2 (8.3)
Submandibulocervical	12 (50.0)
Submandibulocervical and anterior chest wall	5 (20.8)
Others*	5 (20.8)
Etiology	
Odontomandibular	17 (70.8)
Odontomaxillary	1 (4.2)
Injection of caustic substance	2 (8.3)
Idiopathic	4 (16.7)
Complications	
None <sup>‡</sup>	2 (8.3)
Scar (nonlimiting)	11 (45.8)
Scar and functionally limiting contracture	6 (25.0)
Scar and injury to the marginal mandibular nerve	1 (4.2)
Septicemia and death	2 (8.3)

<sup>†</sup>Two patients in this group also presented with bullae formation. <sup>‡</sup>Single cases of renal failure, heart failure, HIV infection, and asthma. \*Single cases of floor of the mouth, infraorbital region, retromolar region, masseteric region, and palate. <sup>‡</sup>The intra-oral sites were single cases of floor of the mouth, retromolar region, and palate. HIV: Human immunodeficiency virus

Our study appears to be the largest series from a single health center in Nigeria. This increased number of cases may be a reflection of this study being a prospective one as opposed to the retrospective analysis of the previous cases.<sup>[11,12,15]</sup> None of the previous local studies included children. The reason for this



**Table 2: Table of means**

	Mean ( $\pm$ SD)	Median	Minimum	Maximum
Age (years)	42.8 ( $\pm$ 22.4444)	39.0	1.5	80.0
Duration before presentation (days)	13.3 ( $\pm$ 5.531)	13.0	6.0	22.0
Span of wound defect (cm)	12.2 ( $\pm$ 8.844)	10.4	3.6	37.0
Span of wound defect for limiting contractures	23.5 ( $\pm$ 13.548)	23.8	4.6	37.0
Span of wound defect for nonlimiting scar	11.1 ( $\pm$ 2.665)	10.6	4.9	17.9
Hospital stay (days)	27.8 ( $\pm$ 23.142)	24.0	2.0	95.0
Duration for wound contraction (days)	34.4 ( $\pm$ 34.500)	19.0	10.0	120.0

SD: Standard deviation

is not known to the authors. However, it is possible that children afflicted with CNF were not brought to the maxillofacial centers then but rather taken to pediatric units of the various hospitals or it could be that pediatric affectation is very rare such that none was captured in the previous years. Nevertheless, despite the involvement of children in this study the mean age of patients is still in the 5<sup>th</sup> decade of life as comparable to previous studies.<sup>[11,12]</sup>

Odontogenic source has been commonly cited as etiology of CNF.<sup>[2,10]</sup> In fact, the two previous studies from this center were both on odontogenic causes alone.<sup>[11,12]</sup> When the infection is secondary to odontogenic origin, the mandibular teeth were the most affected.<sup>[11,12]</sup> Other sources such as peritonsillar abscess, tonsillitis, salivary gland infections, ear infection, insect stings, toothpick injury, injury from stingray, intravenous access, burns, surgical procedures, radiotherapy, steroid neck injections have been documented.<sup>[2,3,16,17]</sup> However, the source is unknown in about 5% of reported cases.<sup>[3]</sup> In our study, majority of the cases were secondary to odontogenic infections, which is in agreement with previous reports.<sup>[11,12]</sup> However in contrast to previous reports, a higher percentage of idiopathic cases were encountered in this study. The other known etiology in our study was the injection of unknown substances into soft tissue by “tradomedical” practitioners for treatment of toothache and keloids, respectively.

Late presentation of patients has been reported by previous authors as one of the major problems to patient management in developing the world, and this has been largely attributed to poverty and ignorance.<sup>[18,19]</sup> In agreement with this, a notable proportion of our patients did not present early and at the time of presentation the overlying skin necrosis had given way to foul smelling wound defects with copious suppuration of brownish, murky serosanguinous (dishwater) discharge, and greyish necrotic tissue as illustrated with cases 2, 3, 4, and 5 of Figure 3. However, a sizeable number of patients presented with swelling alone or swelling and dusky skin appearance [case 1 of Figure 3] and it was relatively easy to differentiate this group of patients from those with fascial space cellulitis or abscess by the minimal or no resistance to exploration with a blunt instrument along the fascial planes during incision and drainage demonstrated by the patients with CNF.<sup>[7]</sup>

The prominent low socioeconomic class representation in our study may be adduced to several factors which include

(1) a possible bias selection of socioeconomically challenged patients attending our hospital; (2) the more affluent individuals having had their odontogenic infections treated promptly did not develop CNF.

A number of systemic conditions have been reported to be associated with CNF and include diabetes mellitus, arteriosclerosis, anemia, malignancies, smoking, alcoholism, advanced age, obesity, hypothyroidism, poor nutritional status, immune-compromising infections (such as human immunodeficiency virus infection and hepatitis B infection) and drugs.<sup>[1-3,7-10,20]</sup> Among the background systemic conditions reported, diabetes mellitus was the most commonly associated.<sup>[3]</sup> However, there have also been reports of this infection in healthy young individuals in whom compromising systemic conditions were not identified.<sup>[3,4]</sup> Majority of our patients had no underlying systemic condition; this is similar to the findings of Obiechina *et al.*, in a previous study done in the same center in which they did not find an association between this infection and compromising background systemic condition. It was suggested that CNF of odontogenic origin may not be associated with compromising systemic condition.<sup>[11]</sup>

Severe infections in the maxillofacial region pose a significant challenge to the maxillofacial surgeon in terms of management. The proximity to the airway and major blood vessels are factors to consider when devising a treatment plan. The management of NF includes urgent systemic resuscitation and surgical intervention in the form of serial debridement under general anesthesia.<sup>[1-3,8]</sup> Incisions are appropriately placed to obtain wide access to all extensions of the infection, and surgical debridement is done extensively until vital bleeding tissues are encountered. Usually, at least two operations of extensive surgical debridement are required.<sup>[3]</sup>

Honey was employed as the dressing agent of choice in the course of management of our CNF patients because of its various advantages. Honey provides a moist environment for wound healing while preventing the growth of bacteria; reduces the malodor associated with tissue necrosis; encourages the outflow of lymph thereby reducing edema and encouraging the nourishment of healing tissue; the glucose contained in honey aids bacteria killing through hydrogen peroxide; the low pH of honey enhances the antibacterial effect of macrophages.<sup>[21,22]</sup> Some honey contain bee defensin, leptosin, and methylglyoxal which

aids antibacterial activity.<sup>[23]</sup> However, there are some potential side effects of honey which include a transient stinging sensation on application (which usually gives way to a soothing effect), possible elevation of blood glucose level in diabetics when applied over a wide area as honey contains 40% glucose (this was not observed in the management of the diabetic patients in our study), dehydration of tissues when applied in the concentrated form and wound botulism as honey is known to sometimes contain the spores of clostridia.<sup>[22]</sup> Some other forms of topical dressings have also been used in the management of CNF such as hydrogen peroxide, normal saline, and betadine dressings, but the frequency of dressing change was up to four times daily.<sup>[7,11,12]</sup> Unlike the twice/once daily regimen employed in our study.

Radiological imaging such as plain radiographs, ultrasonography, computed tomography scan, and magnetic resonance imaging can be helpful in the diagnosis and management of CNF in order to outline the extent of surrounding tissue involvement, relationship of infection to vital structures.<sup>[24,25]</sup> However, just plain radiographs were affordable by our group of patients and were made to include jaw radiographs and chest radiographs.

Being free of the infection did not signify the end of management of these patients but most patients were discharged from in-patient management at this stage after an average of almost a month admission. The occurrence of a clean and granulating wound [Figure 1] heralds yet another challenging stage; wound closure by skin grafting or endurance of a chronic phase of wound dressings and subsequent wound contraction, which took place at an average of 0.5 cm/day [Table 2], usually on out-patient basis. Skin grafting may have prevented the functionally limiting contracture observed in 25.0% of our patient, but the patients could not afford the procedure [Table 1]. The consequent daily hospital attendance and carrying around plastered dressings for a prolonged period of time posed a challenge to this group of patients.

Cervicofacial necrotizing fasciitis has generally been described as a multimicrobial infection, but *Streptococcus haemolyticus*  $\beta$  group A and *Staphylococcus aureus* are commonly implicated.<sup>[1-3,7]</sup> Other bacteria associated are *Enterobacteriaceae*, *Clostridium*, *Klebsiella pneumoniae*, and *Salmonella*.<sup>[2,7]</sup> Gas-forming organisms, classically, Clostridia but may include *Escherichia coli*, *Klebsiella*, *Peptostreptococcus*, and *Bacteriodes* produce insoluble hydrogen, nitrogen, nitrous oxide, and hydrogen sulfide gases that result in subcutaneous emphysema.<sup>[8]</sup> The spectrum of micro-organisms isolated in our study is comparable to literature as *Streptococcus* spp. was the most common isolate. However, about a quarter of cases in the literature showed no growth, a situation which may not be unrelated with poor sample collection technique, use of antibiotics before sample collection for MCS.<sup>[3]</sup> However, a small number (8.3%) was observed to be sterile in our study.

Necrotizing fasciitis has been associated with high morbidity and mortality.<sup>[1,6,7,10]</sup> In the literature, the mortality ranged from 6% to 73%.<sup>[1-3,7,8,14]</sup> It is worthy of note that the mortality rate in

our study (8%) was low compared to the literature despite the challenges encountered in managing this group of patients in our society such as not being able to do initial extensive surgical debridement under general anesthesia and not having the advantages of adjunctive therapy like hyperbaric oxygen therapy. Complications reported in the literature have been mainly of the systemic nature, such as septic shock, disseminated intravascular coagulation, renal and liver failures, and death.<sup>[2,9]</sup> Reports of local complications such as scar formation and functional impairment were sparsely reported. The two deaths recorded in this study were secondary to multiple organ failure from overwhelming sepsis, and local complications were mainly scars which in some cases limited the range of cervical motions especially cervical extension [Table 1].

## CONCLUSION

While our study represents the largest series of CNF from a Nigerian health facility so far, the study also includes the involvement of children and demonstrates that the oral mucosa can be involved in CNF. In our environment, the management of CNF is challenging to both the patient and the surgeon. The surgeon is challenged by the limited available resources while majority of the patients endure a chronic disease process during management.

## ACKNOWLEDGMENT

The authors wish to acknowledge all consultants and nursing staff in the Department of Oral and Maxillofacial Surgery.

## REFERENCES

- Shenoy PK, Bali K. Potentially fatal necrotising fasciitis of the head and neck: A case report and review of the literature. *J Curr Clin Care* 2013;3:28-37.
- Lorenzini G, Picciotti M, Di Vece L, Pepponi E, Brindisi L, Vessio V, et al. Cervical necrotizing fasciitis of odontogenic origin involving the temporal region - A case report. *J Craniomaxillofac Surg* 2011;39:570-3.
- Mastronikolis NS, Stathas T, Naxakis SS, Mallis A, Papadas T, Kalogeropoulou C, et al. Necrotizing fasciitis of the head and neck: Report of 5 cases and review of the literature. *Eur Rev Med Pharmacol Sci* 2010;14:123-34.
- Treasure T, Hughes W, Bennett J. Cervical necrotizing fasciitis originating with a periapical infection. *J Am Dent Assoc* 2010;141:861-6.
- McAllister P, O'Neill F, Bharadwaj G, O'Regan B, Laverick S. A presentation of facial necrotizing fasciitis with orbital involvement. *J Surg Case Rep* 2013;1:3.
- Toran KC, Nath S, Shrestha S, Rana BB. Odontogenic origin of necrotizing fasciitis of head and neck-A case report. *Kathmandu Univ Med J (KUMJ)* 2004;2:361-3.
- Ali MH, Zayed ME. Necrotizing fasciitis of the head and neck: Report of three cases. *Ann Saudi Med* 1997;17:641-5.
- Vaid N, Kothadiya A, Patki S, Kanhere H. Necrotising fasciitis of the neck. *Indian J Otolaryngol Head Neck Surg* 2002;54:143-5.
- Fugitt JB, Puckett ML, Quigley MM, Kerr SM. Necrotizing fasciitis. *Radiographics* 2004;24:1472-6.

10. Subhashraj K, Jayakumar N, Ravindran C. Cervical necrotizing fasciitis: An unusual sequel of odontogenic infection. *Med Oral Patol Oral Cir Bucal* 2008;13:E788-91.
11. Obiechina AE, Arotiba JT, Fasola AO. Necrotizing fasciitis of odontogenic origin in Ibadan, Nigeria. *Br J Oral Maxillofac Surg* 2001;39:122-6.
12. Obimakinde OS, Okoje VN, Akinmoladun VI, Fasola AO, Arotiba JT. Retrospective evaluation of necrotizing fasciitis in University College Hospital, Ibadan. *Niger J Clin Pract* 2012;15:344-8.
13. Oyedeji GA. Socioeconomic and cultural background of hospitalized children in Ilesha. *Niger J Paediatr* 1985;12:111-7.
14. Wolf H, Rusan M, Lambertsen K, Ovesen T. Necrotizing fasciitis of the head and neck. *Head Neck* 2010;32:1592-6.
15. Ndukwe KC, Fatusi OA, Ugboko VI. Craniocervical necrotizing fasciitis in Ile-Ife, Nigeria. *Br J Oral Maxillofac Surg* 2002;40:64-7.
16. Gilad J, Borer A, Weksler N, Riesenber K, Schlaeffer F. Fatal necrotizing fasciitis caused by a toothpick injury. *Scand J Infect Dis* 1998;30:189-90.
17. Gibboney W, Lemons JA. Necrotizing fasciitis of the scalp in neonates. *Am J Perinatol* 1986;3:58-60.
18. Oji C. Late presentation of orofacial tumours. *J Craniomaxillofac Surg* 1999;27:94-9.
19. Obiadazie AC, Agbara R, Okeke U, Adeola DS, Bassey GO. Challenges of reconstructing mandibular defects following tumour surgeries at Zaria, Nigeria. Illustrating with two cases. *Glob Res J Med Sci* 2013;3:12-9.
20. Tambuwala A, Rangoonwala MA. Necrotising Fasciitis of the Head and Neck Secondary to a Dental Infection - A Rare Case Report. Available from: <http://www.guident.net/oral-surgery/necrotising-fasciitis-of-the-head-and-neck-secondary-to-a-dental-infection-a-rare-case-report.html>. [Last accessed on 2013 Dec 24 at 22:01].
21. Molan P. Why honey is effective as a medicine. Available from: <http://www.researchcommons.waikato.ac.nz/bitstream/handle/10289/2059/?sequence=1>. [Last accessed on 2013 Dec 24 at 9:16 am].
22. Molan PC. The evidence for honey promoting wound healing. A brief review of the use of honey as a clinical dressing. Primary intention. *Aust J Wound Manage* 1998;6:148-58.
23. Seckam A, Cooper R. Understanding how honey impacts on wounds: An update on recent research findings. Available from: <http://www.woundsinternational.com/practice-development/understanding-how-honey-impacts-on-wounds-an-update-on-recent-research-findings>. [Last accessed on 2013 Dec 20 at 2:30 pm].
24. Becker M, Zbären P, Hermans R, Becker CD, Marchal F, Kurt AM, *et al.* Necrotizing fasciitis of the head and neck: Role of CT in diagnosis and management. *Radiology* 1997;202:471-6.
25. Ali SZ, Srinivasan S, Peh WC. MRI in necrotizing fasciitis of the extremities. *Br J Radiol* 2014;87:20130560.

**How to cite this article:** Olusanya AA, Gbolahan OO, Aladelusi TO, Akinmoladun VI, Arotiba JT. Clinical parameters and challenges of managing cervicofacial necrotizing fasciitis in a sub-Saharan tertiary hospital. *Niger J Surg* 2015;21:134-9.

**Source of Support:** Nil, **Conflicts of Interest:** None declared.

