

## PREGNANCY FOLLOWING LAPAROSCOPIC OVARIAN DRILLING FOR CLOMIPHENE RESISTANT POLYCYSTIC OVARIAN SYNDROME

\*JI Ikechebelu, \*SU Mbamara, \*\*CAF Okeke

Department of \*Obstetrics/Gynaecology, Nnamdi Azikiwe University Teaching Hospital, Nnewi,  
\*\*Fertility Unit of Life Specialist Hospital Ltd, Nnewi, Nigeria.

### ABSTRACT

We present a case of a 29 year old nulliparous woman with clomiphene resistance polycystic ovarian syndrome. She had a successful laparoscopic ovarian drilling (LOD) in a private fertility centre in Nnewi Southeast Nigeria. She achieved a pregnancy four months later following clomiphene citrate ovulation induction. The pregnancy was complicated with 1<sup>st</sup> trimester threatened abortion, pre-term PROM and later pre-term labour at 34 weeks gestation with breech presentation. She had a successful caesarean delivery of a 1.75kg life female baby that was nursed in the incubator for 2 weeks before discharge. This is the first reported successful LOD in Southeast Nigeria with good pregnancy outcome.

**Key Words:** PCOs, Clomiphene citrate, Laparoscopic Ovarian Drilling (LOD). (Accepted 14 April 2009)

### CASE REPORT

Mrs V.I. was a nulliparous woman who presented on 28 Dec 2006 at the age of 29 years with primary infertility of 18 months duration. She was a self employed university graduate while her husband was a civil servant. They lived in Lagos Southwest Nigeria. She married 18 months earlier but was unable to achieve any pregnancy despite adequate unprotected sexual intercourse. She had episodes of irregular menstruation characterised by oligomenorrhoea and periods of amenorrhoea. She had visited several hospitals & clinics where ultrasound done suggested polycystic ovaries and hormonal assay showed a reversal of FSH/LH ratio and increased androgen level. She gave a history of treatment with Parlodel (Bromocriptine) although there was no history of expressible galactorrhoea and prolactin was not raised on the hormone assay. She had undergone ovulation induction with clomiphene citrate (up to 150mg daily) and timed intercourse for about 8 months prior to presentation without any success. She neither smoked cigarettes nor drank alcohol.

Examination revealed an obese (BMI 30) woman with male pattern of hair distribution. Her blood pressure was 120/80mmHg and her pulse was 80 beats per minute. Her chest was clinical clear and there was nothing significant in the abdominal examination. Her PCV was 33%, blood group O Rhesus D positive, haemoglobin genotype AA and urinalysis was normal. She was HIV negative. Her husband's seminal fluid analysis parameters were within normal range. The results of the investigations, diagnosis and management options

were explained to the couple and they gave their consent for laparoscopic ovarian drilling.

She had Laparoscopic ovarian drilling under general anaesthesia on 11th Jan. 2007. Three-port laparoscopy was done. The 10mm port was placed on the infra umbilical crease via a transverse incision and two 5mm ports were placed at both sides 5cm away from the umbilical port using base-ball diamond concept<sup>1</sup>. The intra-operative findings include normal sized uterus with 2cm subserosal fibroid, 9cm uterine cavity and nulliparous cervical os, normal tubes and clear peritoneal cavity with no adhesions. The ovaries were large measuring about 5 x 6cm and appear polycystic. Other intra-abdominal organs were normal. There was prompt bilateral spillage of dye (methylene blue) from both fallopian tubes. Bilateral ovarian drilling was done using 40watts of cutting current, 4mm depth and for 4 seconds. Our first step in drilling is to lift the ovaries out of the ovarian fossa. We then used Nutan Jain's technique<sup>2</sup> of lifting the ovaries by an irrigation canula inserted through an ipsi-lateral lower abdominal 5mm port. The canula is wedged against the cervico-uterine junction, giving a strong platform for drilling. A good uterine manipulator is used to manipulate the uterus. The monopolar needle is inserted from the contra-lateral 5mm port and approaches the ovaries at right angles. Six drills were made on each ovary. There was minimal blood loss and generous suction irrigation of the ovaries and peritoneal lavage with normal saline was done after the drill to cool the ovaries and clear the pelvis of any blood clots and debris. After the procedure, the instruments were removed first and then the 5mm trochars under vision and the laparoscopy and the 10mm trochar subsequently. The port wounds were closed by subcuticular suturing using chromic

---

Correspondence: Dr JI Ikechebelu  
Email: jikechebelu@yahoo.com

catgut 2/0.

Two weeks after the operation on 25<sup>th</sup> Jan. 2007; she had her menstrual flow with dysmenorrhoea. The flow was heavy and in clots (used 3-4 pads daily) and lasted for 5 days. She was seen again 4 months later on 5<sup>th</sup> May with two months amenorrhoea. Urine pregnancy test was negative and ultrasound evaluation showed estrogenised endometrium and she was given a progesterone challenge with Primolut N 5mg tds for 5 days. Subsequently her menstrual period started on 14<sup>th</sup> May 2007 with normal 5 days flow and no dysmenorrhoea. She received clomiphene citrate 100mg from days 2 to 6 of the cycle and had adequate sexual exposure with the husband during her ovulation period between the 12 and 15 days of her cycle as determined with ovulation test kit. She missed her next menses and subsequently took a urine pregnancy test at 5 weeks amenorrhoea on 16<sup>th</sup> June 2007, which was positive. The pregnancy was later confirmed by ultrasound. She had threatened abortion at 7 and 11 weeks gestation respectively with spotting of blood per vaginam only. This responded to bed rest and primolut depot injections. The pregnancy thereafter progressed normally until 34 weeks gestation when she had pre-term PROM and latter went into spontaneous preterm labour. She was delivered of a live female baby on 12<sup>th</sup> Jan 2008 by a caesarean section due to prematurity and breech presentation. The baby weighed 1.75kg and was nursed in the incubator for 2 weeks before discharge.

Figure 1: **Lt. Ovary before Drilling.**

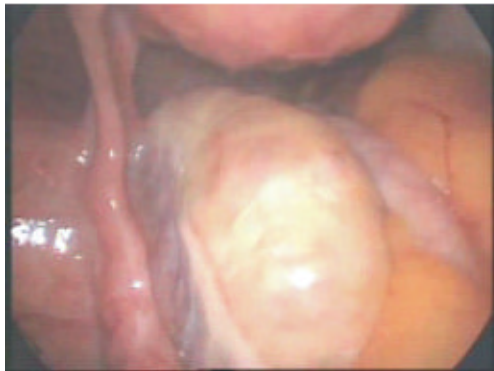

Figure 2: **Dye Test (Methylene blue) +ve Spillage.**

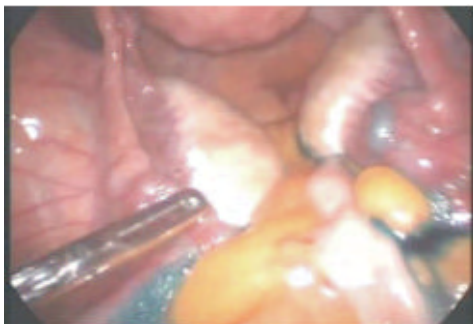

Figure 3: **Rt. Ovary during Drilling.**

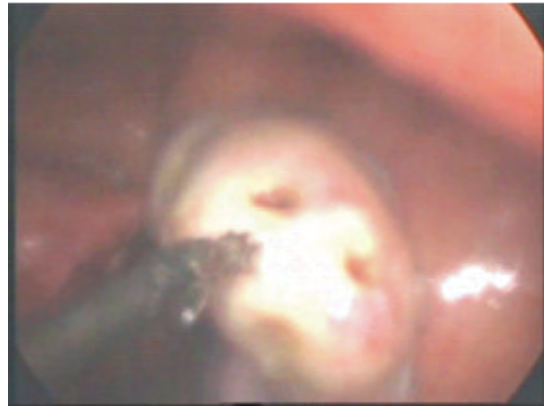


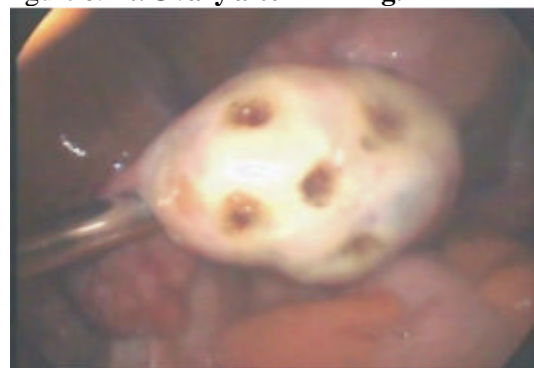
Figure 4: **Rt. Ovary after Drilling.**

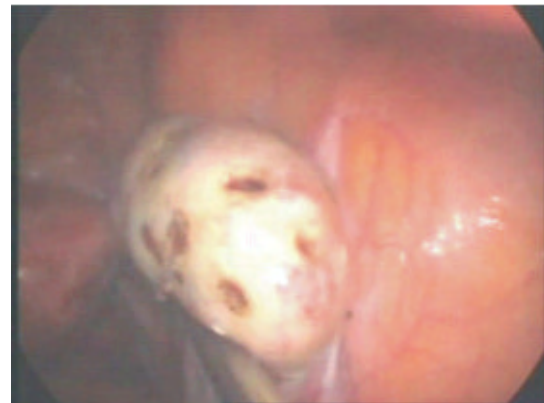

Figure 5: **Generous Irrigation after Drilling.**

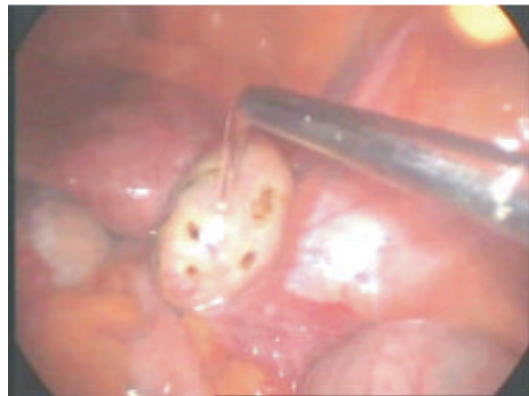

Figure 6: **Lt. Ovary after Drilling.**



## DISCUSSION

Polycystic ovarian syndrome is the most common cause of chronic anovulation and secondary amenorrhoea in women<sup>3</sup>. Other symptomatology of the disease includes obesity, hirsutism, and oligomenorrhoea. The diagnosis of PCOS in our patient was based on the presence of all the above symptoms, the trans-vaginal ultrasound report which revealed large volume ovaries with small peripheral follicles and supported by reversal of the FSH/LH ratio. Our patient had undergone menstruation induction with progestogens before marriage and failed ovulation induction with clomiphene citrate prior to presentation. Clomiphene citrate is widely accepted as the first line treatment for ovulation induction for infertile women with PCOS<sup>3</sup>. The modalities of treatment of women who are non-responsive to ovulation induction with clomiphene (clomiphene resistant ovaries) include medical treatment with Gonadotrophin and/or metformin as well as ovarian drilling<sup>3,4</sup>. Surgical ovarian wedge resection was the first treatment for women with anovulatory PCOS but was largely abandoned due to the risk of post-surgical adhesions and introduction of medical induction with clomiphene citrate and gonadotrophins<sup>5</sup>. Women who are treated with gonadotrophins require intensive monitoring; often have over-production of follicles, which may result in ovarian hyperstimulation syndrome (OHSS) and multiple pregnancy<sup>5</sup>. It is also very expensive and unaffordable for most couple in our society (without health insurance policy) as a monthly treatment. Our patient preferred the one time cost of laparoscopic ovarian drilling (LOD) after counselling. Hence she had LOD which eliminates the complications of gonadotrophic treatment.

This is the first LOD ever done and reported from our centre and the entire Southeast Nigeria. Ovarian drilling and wedge resection are well accepted interventions for ovulation induction in clomiphene citrate polycystic ovarian syndrome patients. The procedure was done with minimal trauma, short hospital stay and no complication. Just like in our patient whose menstruation returned spontaneously and who ovulated and conceived with her first clomiphene ovulation induction within four months of the procedure; other observational studies have reported that ovarian drilling is followed temporarily by a high rate of spontaneous ovulation and conception or that subsequent medical ovulation induction becomes much easier<sup>5,6</sup>.

The mechanism of action of LOD is unknown; however, it is associated with a reduction in serum androgen level, improved spontaneous ovulation and improved fertility in women with PCOS. Post-operative adhesion and premature ovarian failure are assumed adverse effects of LOD. Ultrasound guided transvaginal ovarian needle drilling (UNTND) is an alternative method of ovarian drilling which is

assumed to be as effective as LOD in resumption of menstruation, resolution of hirsutism, reduction in LH/FSH ratio, ovulation and pregnancy rate<sup>7</sup>.

The complications in pregnancy seen in our patient included threatened abortion, pre-term PROM, breech presentation, and premature delivery. There is no reported evidence of a difference in live birth and miscarriages in women with PCOS undergoing LOD compared to gonadotrophin treatment<sup>5</sup>. Other complications in pregnancy reported in women with PCOS who conceive after LOD are increased risk of impaired glucose tolerance (IGT), gestational diabetes mellitus (GDM), and raised blood pressure<sup>8</sup>. LOD is therefore a viable alternative in the further management of our women with infertility due to clomiphene resistant PCOS.

## REFERENCES

1. **Mishra RK.** Principle of laparoscopic port position. In Textbook of practical laparoscopic surgery. Jaypee Brothers Medical Publishers, New Delhi. 2008. Pp. 83-86.
2. **Nutan Jain.** Laparoscopic management of polycystic ovaries. In Nutan Jain (Ed) State of the Art Atlas of Endoscopic Surgery in Infertility and Gynaecology. Jaypee Brothers Medical Publishers, New Delhi. 2007. Pp. 213-214.
3. **Seow KM, Juan CC, Hwancy JL, Ho LT.** laparoscopic surgery in polycystic ovarian syndrome: reproductive and metabolic effects. *Semin Reprod Med.* 2008. 26(1): 101-10.
4. **Youssef H, Atallah MM.** Unilateral ovarian drilling in polycystic ovarian syndrome: a prospective randomized study. *Eprod Biomed on line.* 2007. 15(4): 457-62.
5. **Farquhar C, Lilford RJ, Marjoribanks J, Vandekerckhove P.** laparoscopic "drilling" by diathermy or laser for ovulation induction in anovulatory polycystic ovarian syndrome. *Cochrane database syst rev.* 2007. 18;(3): CD001122.
6. **Palomba S, Orio F Jr, Falbo A, Russo T, Cateri MG, Manguso F, et al.** Metformin administration and Laparoscopic ovarian drilling improve ovarian response to clomiphene citrate (CC) in oligo-anovulatory CC resistant women with polycystic ovarian syndrome. *Clinic Endocrinol (Oxf).* 2005. 63(6): 631-5.
7. **Badawv A, Khilary M, Ragab A, Hassan M, Sherif L.** Ultrasound-guided transvaginal ovarian needle drilling (UNTND) for treatment of polycystic ovarian syndrome: A randomized controlled trial. *Fertil Steril.* 2008. Mar 13 [Epub ahead of print].
8. **Al-Ojaimi EH.** Pregnancy outcomes after laparoscopic ovarian drilling in women with polycystic ovarian syndrome. *Saudi Med J.* 2006. 27(4): 519-25.