

Ward Round – Cough, painful throat and progressive hoarseness of voice for 1 year

Theresa Allain¹, Kondwani Katundu¹, Wakisa Mulwafu²

1.Dept of Medicine College of Medicine, University of Malawi

2.Dept of Surgery College of Medicine, University of Malawi

Clinical presentation

A 30 - year old fisherman was admitted to the medical ward at Queen Elizabeth Central Hospital, Blantyre as a referral from Chikwawa District Hospital with a one year history of cough, painful throat, hoarse voice and difficulty swallowing.

The cough was productive of cream colored sputum with no blood staining. There were no relieving or exacerbating factors and there was no diurnal variation in the intensity of coughing. He also had a sore throat and chest pains which were burning in nature. Five months after the onset of the cough he developed hoarseness of voice which became progressively worse. He experienced a “burning sensation” when speaking. Within this period, he also developed pain and difficulties in swallowing both solid foods and water. Dysphagia for fluids started at the same time as dysphagia for solids.

Three months prior to admission, the patient noted that there was slight protrusion of his throat which was tender on touch. He also had a sensation of a rough mass in his throat and hence could often clear his throat.

He had a history of intermittent night sweats, fevers and weight loss, which he was not able to quantify. He also described dyspnoea on exertion. However, he had normal appetite, no abdominal pains and normal bowel habits. There was no history of ear pain or TB contact. The cough had not responded to Amoxicillin and Erythromycin which had been prescribed by a local health centre in his area.

He never smoked nor took any form of alcohol. However, for many years he had worked as a fish smoker.

On examination, he was, alert with a fair nutritional status and not in obvious respiratory distress. The conjunctivae were pink and there was no jaundice. There was no finger clubbing. He was afebrile with a temperature of 36.8 °C , pulse rate 80/ min, respiratory rate of 20 breaths/min and a blood pressure of 110/70 mmHg. He had a hoarse voice and was often clearing his throat and coughing. The cough had a “bovine” quality. The uvula was not deviated and there was normal movement of the pharynx, normal sensation in the oropharynx, an intact gag reflex and no stridor was heard. He had bilateral cervical lymphadenopathy in the posterior triangle of the neck. The lymph nodes were mobile, not matted, with sizes ranging from 0.5-2cm in diameter.

Bilateral crepitations were heard on chest examination. The cardiovascular and abdominal examinations were unremarkable.

Questions

1. Based on the history and examination described above what are the important differential diagnoses to consider?
2. What investigations should be done?

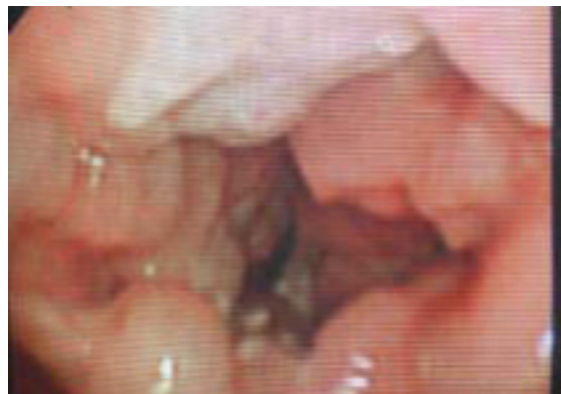
The important diagnoses to consider are either;

- Malignant process
- Infectious process

Fig 1 CXR showing right sided perihilar infiltrates

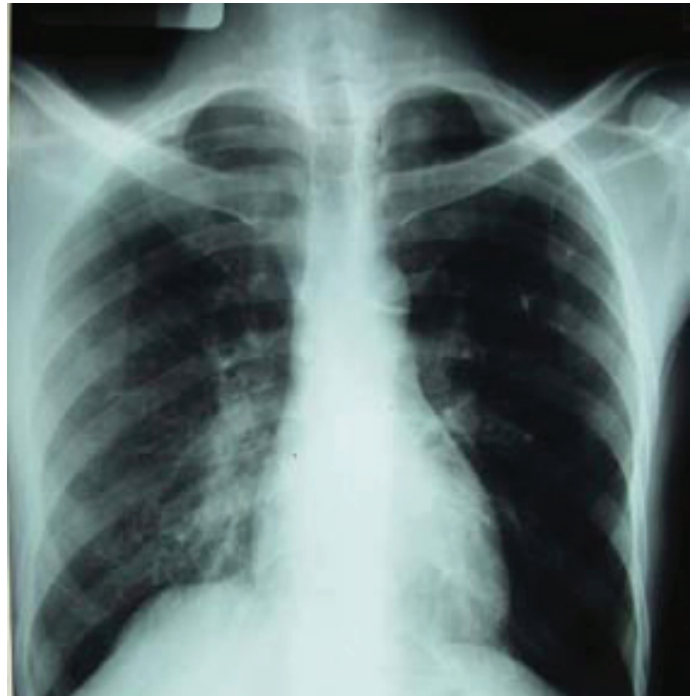

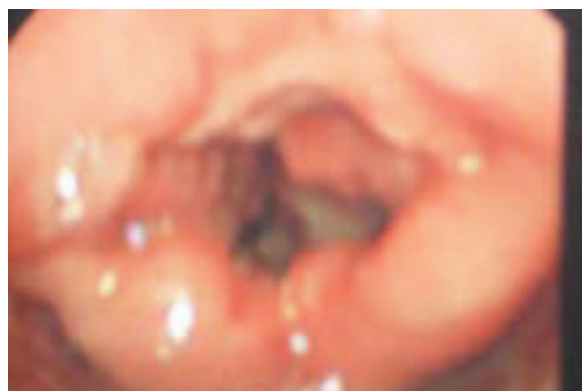Fig 2 A focussed view of the destroyed vocal cords.



Figures 3 Panoramic view of the larynx



The progressive hoarse voice and bovine cough point to a laryngeal disorder due either to a direct destructive process to the larynx or to a laryngeal nerve palsy, for example associated with thyroid or lung malignancy. The difficulty swallowing suggests the problem may also be involving the postcricoid space or pyriform fossa.

The symptoms began with cough- this may indicate a primary pulmonary pathology such as carcinoma of the lung or a chronic lung infection, such as TB. Alternatively the cough could be secondary to chronic aspiration caused by a pharyngeal or laryngeal pathology or could be due to metastases from a primary malignancy in the throat, thyroid or elsewhere. Among the risk factors identified for laryngeal TB are the consumption of tobacco, alcohol, malnutrition and immunodeficiency. Our patient had a high exposure to biomass fuel through his occupation. Biomass fuel exposure, including wood smoke, has been linked to carcinoma of the larynx¹, and also to pulmonary TB² but not specifically laryngeal TB. Rarer diagnoses that should be considered include chronic granulomatous diseases like blastomycosis, histoplasmosis, coccidioidomycosis, sarcoidosis, syphilis, Wegener's granulomatosis, granuloma inguinale, actinomycosis and leishmaniasis. Of all these possibilities the progressive nature of his symptoms made us think the most likely clinical diagnosis was carcinoma of the larynx.

Investigations

Prior to transfer to the medical ward he had already had a barium swallow which was reportedly normal. We did not see the pictures to confirm this.

Investigations done by us were as follows:

- FBC: Hb 12.3 g/dl, MCV 78 fl, WBC 7.2 *10⁶ /μL, Platelet 209 *10⁶ /μL
- VDRL was negative
- His HIV test was negative
- Sputum samples were positive for AFBs

CXR Showed right perihilar infiltrates (Figure1)

Laryngoscopy revealed a mass located in the posterior part of the larynx and the pyriform fossa with complete destruction of the vocal cords with loss of mobility, Figures 2 and 3. There was loss of detail in the anatomy of the larynx. There was associated swelling of the arytenoids and postcricoid space which is consistent with laryngeal pharyngeal reflux. Laryngeal pharyngeal reflux could explain the symptoms of feeling of mass in the neck, throat clearing, dysphagia and burning sensation in the throat and chest.

It was not possible to know if the mass was invading surrounding tissues as the patient did not undergo CT or MRI.

- A Biopsy of the mass in the larynx was done and sent to the College of Medicine laboratory for histology and results showed "tiny fragments of necrotizing tissue surrounded by histiocytes and lymphocytes whose feature were consistent with "tuberculosis".

Further progress

On receipt of the sputum results the patient was put on standard treatment for smear positive pTB with rifampicin, isoniazid, ethambutol and pyrizinamid. The laryngoscopy and histological findings additionally confirmed the diagnosis of laryngeal tuberculosis.

He responded well after some days on TB treatment. He was

counseled and encouraged to rest his voice and use other modes of communication until he got better. He was advised on safe ways of feeding since he had a risk of aspiration. There was need to monitor his nutrition considering that he had problems feeding to make sure that he did not lose weight.

Discussion

Laryngeal TB is uncommon and said to be 1% of all extra pulmonary TB cases and there are relatively few cases reported in literature³. The disease usually co-exists with pulmonary TB as was the case here⁴. Laryngeal TB is commonly secondary to a tuberculous lesion elsewhere and rarely a primary infection due to inhaled tubercle bacilli settling directly⁵.

The patient's age reported in this case was lower than most cases reported elsewhere⁴. This could be due to differences in environmental and ethnic factors. The clinical features of laryngeal TB demonstrated here are relatively typical of what was reported in most other cases with laryngeal symptoms being hoarseness, sore throat and dysphagia⁴. Pulmonary and constitutional symptoms presented in this case pointed to the pulmonary involvement. The variable clinical features of laryngeal TB make the differential diagnosis a challenge⁵ as was in this case where the main differential diagnoses were laryngeal tumor and chronic laryngitis from other causes e.g. syphilis and laryngeal pharyngeal reflux.

As in this patient, most cases of laryngeal TB respond well to treatment within 72 hours from commencement of anti - TB drugs and other symptoms like hoarseness of voice subside in weeks.

Though a rare condition, laryngeal TB should be considered in patients thought to have other forms of chronic laryngitis and laryngeal carcinoma since the disease is highly contagious but treatable. We were fortunate in that our patient had sputum positive TB, so we reached a diagnosis quickly. The case illustrates the importance of considering TB in the differential diagnosis of laryngeal pathology and obtaining a biopsy in unexplained laryngeal pathology. It also illustrates the importance of considering the patients occupation when considering the differential diagnosis.

References

1. Torres-Duque C, Malandano D, Perez-Padilla R, Ezatti M and G Vieggi. Biomass fuels and respiratory diseases: a review of the evidence. *Proc Am Thorac Soc* 2008; 5: 577-90
2. Kolappan C and Subramani R. Association between biomass fuel and pulmonary tuberculosis: a nested case control study. *Thorax* 2009; 64: 705-8
3. Tesic-Vidovic L. Laryngeal Tuberculosis. A Report of Three Cases. *The Internet Journal of Otorhinolaryngology*. 2006; 4: 2
4. Mehndiratta A, Bhat P, D'Costa L, Mesquita A.M and Nadkarni N. *Primary Tuberculosis of the Larynx. Ind J Tub* 1997; 44:211.
5. Shin J.E, Nam S.Y, Yoo S.J and Kim S.Y: Changing trends in clinical manifestations of laryngeal tuberculosis. *Laryngoscope* 2000; 110:1950-1953.
6. Pease B.C, Hoasjoe D.K and Stucker F.J: Videostroboscopic findings in laryngeal tuberculosis. *Otolaryngol Head Neck Surg* 1997; 117(6):S230:234.