

Ward Round in Moyo House- Management issues in malnourished children with HIV and Tuberculosis (TB)

Erica Hayes, Ajib Phiri, Tom Heikens

1. Department of Paediatrics & Child Health, College of Medicine and Queen Elizabeth Central Hospital, Blantyre, Malawi.

Case 1

GB is a 4 month old male currently living with his aunt. His mother is deceased and nothing is known about the mother's health or the birth history. Over the last 4 weeks, GB developed worsening watery non-bloody diarrhea and felt warm to his caregivers. Over the last week his oral intake decreased significantly; he is being fed formula and phala (soft maize porridge).

On examination, GB appears very wasted and is irritable. His weight is 2.8 kilograms; his length is 58 centimeters which calculates to a weight for height Z score (WHZ) of -4.0. His temperature is 34.6 C. His heart rate is 180/min. Respiratory rate is 60/min. His skin hangs loosely and he has very little muscle mass. In his oropharynx he has thick white plaques covering his tongue and his mucous membranes are dry. His lungs are clear and he has minimal retractions. His heart exam is notable for a prominent visible heart pulsations due to his thin body habitus. There are no appreciable murmurs or gallops. He has good bowel sounds, with a liver edge palpable 2 centimeters below the right costal margin and a palpable spleen tip. He also has diffuse lymphadenopathy.

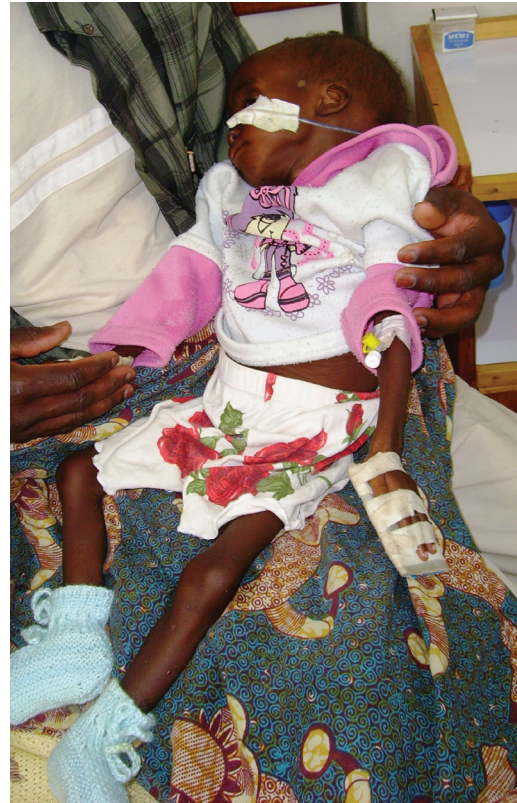The infant is admitted and management is started for his malnutrition. The doctor also orders an HIV test which comes back reactive.

Questions for Case 1:

1. **Would this presentation be typical for an HIV infected infant?**
2. **How can you definitively diagnose HIV infection in this child and when should the testing be done?**
3. **Does this child qualify for ARV treatment under the current guidelines for antiretroviral therapy in Malawi?**
4. **When would you start HIV treatment in this child?**
5. **Is it likely that the child will improve significantly with only renourishment?**

Case 2

CD is an 18 month old HIV infected female who has been on ARVs for 6 weeks admitted to a nutritional rehabilitation unit for the third time in 4 months. CD has had a fever daily for the past 2 weeks and has been coughing for 3 months per her mother's report, and seems to be worsening. CD has a documented weight loss since her discharge 8 weeks earlier of 400 grams. When queried about adherence to ARVs and co-trimoxazole, the mother reports 100% adherence and pill counts support this. On exposure history, it is revealed that the child's mother was diagnosed 4 months earlier with smear negative tuberculosis (TB) and was started on therapy. The mother has improved on therapy and gained weight. CD's 4 year old sister has also been coughing for 2 months with low



grade fevers. She is also reactive and has been on ARVs for 1 year and is doing well otherwise.

On examination, CD is very wasted and quite fussy. She coughs frequently and forcefully throughout the exam. Her weight is 6 kilograms and her length is 72 cm., with a WHZ score of -3.5. The child has oropharyngeal thrush involving the entire mouth and palate. Her lung exam reveals crepitations on the right side. She also has a candidal infection in her vaginal area. Her liver is 1 centimeter below the right costal margin. The remainder of her exam is unremarkable.

Given the history and physical findings, the physician orders Mantoux testing on both CD and her older sister which are read 48 hours after placement. CD's test has an induration is 10 millimeters while her sister's was negative with no induration.

Questions for Case 2:

1. **Are the Mantoux test results surprising?**
2. **How would you determine if CD has a latent TB infection or active TB disease?**

Ward Round - Management issues in malnourished children with HIV and Tuberculosis (TB)

Continued from page 120

Discussion of case 1

1. This infant is presenting with severe malnutrition in the form of marasmus. Children with HIV frequently present with wasting and $\geq 50\%$ of children seeking care for severe malnutrition are HIV infected in some sites in sub-Saharan Africa. Marasmus has been the form of malnutrition most associated with HIV infection; however infants and children may also present with kwashiorkor or a combination of both forms (marasmic kwashiorkor). Severe malnutrition itself causes a secondary immunodeficiency.

2. The HIV ELISA (antibody) test in the infant less than 18 months of age reflects maternal antibodies to HIV that have crossed the placenta. It confirms in utero HIV exposure but not infection. In order to make the diagnosis of HIV infection in the infant you must test the infant to see if he has the virus present in his blood by performing a HIV DNA PCR.

Infants of reactive mothers should be tested ideally at 6 to 8 weeks of age, as HIV infection acquired through the birth process should be detectable by that time; this is the mode of infection of the vast majority of infants. Breastfeeding is another way in which HIV can be transmitted; to confirm a negative status, the child must be tested 3 months after cessation of breastfeeding. For children greater than 18 months of age who are not breast feeding, an HIV ELISA test can be used as the sole diagnostic test. GB's PCR result was positive.

3. The child in the vignette does qualify for treatment. It is recommended that all infants less than 12 months of age be treated with ARVs because of the high incidence of opportunistic infections and death in young infants with untreated HIV. Aside from age, the patient's severe malnutrition status is also a WHO Clinical Stage 4 finding that would meet criteria for treatment as well. The table below summarizes the current guidelines for starting antiretroviral therapy in Malawi. Meeting either the CD4 or clinical criteria qualifies a child for treatment. Note that in children less than 5 years of age CD4 percentages should be used when evaluating

CD4 qualifications for ARV treatment.

4. HIV treatment should be started as soon as feasible in this infant. The importance of early treatment of HIV in infants has been demonstrated by the CHER study (Children with HIV Early Anti-Retroviral Therapy) performed in South Africa and published in late 2008. This was a study of 380 South African infants aged 6 to 12 weeks. In this study, 2/3 the group was randomized to start immediate early ART (i.e. while essentially asymptomatic) while the other 1/3 was randomized to a deferred therapy per WHO clinical guidelines. They found a 76% reduction in mortality in the early treatment group through 15 months of age as well as a 75% reduction in progression in clinical stage of the infants' HIV disease. Overall, the infants tolerated ARVs well. For malnourished children, there is not as much data on ARV start but the data that exists strongly supports early treatment. This is an area that merits further study.

5. It is not likely that the child will improve on renourishment alone. In studies done on nutritional rehabilitation programs, HIV non-reactive infants have been shown to have significantly better survival compared with their HIV infected peers. Strong evidence supports that recovery in these children is dependent on timely nutritional rehabilitation and ARV therapy.

AGE	<12 Months	1-3 Years	3-5 Years	>5 Years of age
CD4 Criteria (% or absolute count)	All infants should be treated regardless of CD4 or clinical criteria	$\leq 20\%$	$\leq 15\%$	$\leq 15\%$ or absolute CD4 count of 250
Clinical Criteria		WHO Clinical Stage 3 or 4	WHO Clinical Stage 3 or 4	WHO Clinical Stage 3 or 4

Ward Round - Management issues in malnourished children with HIV and Tuberculosis (TB)

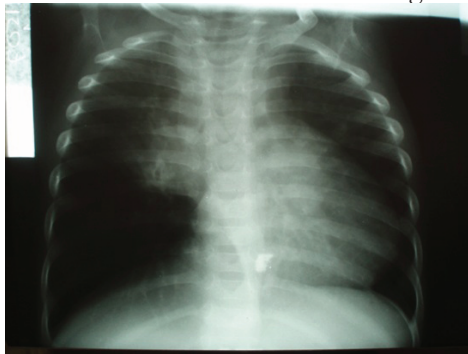
Continued from page 120

Discussion of Case 2

1. The Mantoux results, though inconsistent between the sisters, are not surprising. Mantoux testing in the immunocompromised child can be quite unreliable due to anergy, therefore a negative Mantoux does not rule out active TB infection in these children. Children with disseminated or miliary TB are also often Mantoux negative. CD's positive Mantoux test given her level of immune suppression is strongly suggestive of TB infection in this immunocompromised child.

2. The positive Mantoux test confirms that CD is infected with TB. To determine if CD has active TB disease, we must review her symptoms as well as obtain a chest x-ray (CXR). Even if the CXR were negative, given CD's poor immune status and consistent symptoms, she meets a clinical diagnosis of active TB infection and should be treated accordingly (see answer 5). If she were a well asymptomatic child with a negative CXR, the diagnosis would be latent TB infection and prophylaxis with 6 months of isoniazid would be indicated.

3. Chest X-ray findings in tuberculosis can be quite varied, ranging from paratracheal and hilar adenopathy to atelectasis of lobes (from airway compression from adenopathy) to a widened mediastinum to parenchymal findings. Other findings include a diffuse or miliary pattern (often described as a snow storm appearance), pleural effusions, and cardiomegaly (in the case of TB pericarditis with effusion). It is rare that children develop the cavitory disease seen in adults, but can be seen in adolescents; they are usually thin walled in appearance on CXR. Fortunately, young infants and children are not highly contagious for TB because of the absence of cavitation and weak cough.



Chest X-ray showing bilateral perihilar lymphadenopathy, widening of mediastinum and splaying of the carina.

4. Though much is made of the highly contagious nature of sputum positive TB, it should be realized that sputum negative TB is far more prevalent and likely accounts for many more secondary infections. In one model of TB infection patterns it is estimated that smear positive individuals are 6 times more likely to transmit the infection to others. However, the ratio of smear negative to smear positive individuals in the population is estimated to be 35 to 1.

5. Standard therapy for treatment of pulmonary TB in Malawi includes the drugs Isoniazid (H), Rifampicin (R), Pyrazinamide (Z) and Ethambutol (E). For sputum positive TB, treatment is with RHZE 3 times weekly for 2 months

followed by EH daily for 6 months. For sputum negative TB, RHZ is used for the initial phase. Sputum is often difficult to obtain from young children, but it should be attempted to try to determine sputum status as well as attempting to grow the bacteria so that it may be tested for susceptibilities if indicated. Another approach is to obtain sputum from the patient's mother or symptomatic adults who care for the child.

To recover, both TB treatment and ARVs are needed. Treating the TB first may decrease the likelihood of immune reconstitution syndrome (see answer 6). If TB treatment is started prior to ARVs, the TB drugs should be allowed to attain steady state. Old recommendations were to wait at least 2 months before starting ARVs; however, this timetable may be able to be moved up to starting ARVs 2 to 4 weeks after TB treatment in select severely immunocompromised children in need of urgent ARV therapy.

Rifampicin interacts with nevirapine, one of the three drugs given in the ARV regimen. Rifampicin increases the metabolism of nevirapine, resulting in lowered nevirapine levels. Because of this, children on TB therapy who are starting ARVs should start on full dose nevirapine and not the initial 2 week lead in of half dose nevirapine that is standardly done in patients not on TB therapy.

6. CD's course is suggestive of Immune Reconstitution Inflammatory Syndrome, abbreviated as IRIS. IRIS is seen in severely immunocompromised individuals who achieve immunological recovery be it from ARV therapy, improvement in severe malnutrition, or discontinuation of medicines that suppress the immune system. In their suppressed immunologic state, patients often have

smoldering infections that have not clearly demonstrated themselves due to the absence of inflammation which would normally be caused by a healthy immune system. When the immune system recovers, it then sees these infections and attacks them exuberantly, resulting in a potentially overwhelming inflammatory state.

IRIS has been described in patients who have been on ARVs for weeks to months, although it is usually seen on the earlier end of this spectrum. Other infections with which IRIS can be seen include Pneumocystis pneumonia, cryptococcal meningitis, and hepatitis. Unfortunately, in the severely suppressed patient, distinguishing between IRIS and a new serious infection is difficult; IRIS must be considered a diagnosis of exclusion. Further work to define consistent clinical criteria to define IRIS is needed.