

## Review article

### Mast cell activation disease

**Hanan Abd El Lateef**

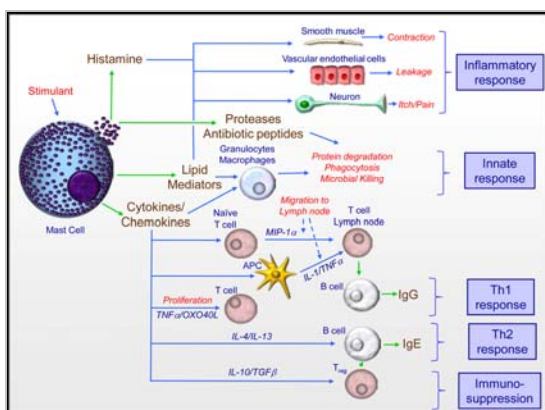
Lecturer in Pediatrics, Ain Shams University, Cairo

Mast cells are multifunctional cells that initiate not only IgE dependent allergic diseases but also play a fundamental role in innate and adaptive immune responses to microbial infection. They are also thought to play a role in angiogenesis, tissue remodeling, wound healing, and tumor repression or growth. The broad scope of these physiologic and pathologic roles illustrates the flexible nature of mast cells, which is enabled in part by their phenotypic adaptability to different tissue microenvironments and their ability to generate and release a diverse array of bioactive mediators (Figures 1 and 2) in response to multiple types of cell surface and cytosolic receptors.<sup>1</sup> Mast cells are tissue fixed effector cells of allergic and other inflammatory reactions. In common with blood basophils mast cells express high affinity IgE-binding sites and store numerous proinflammatory and vasoactive mediators in their metachromatic granules.<sup>2</sup>

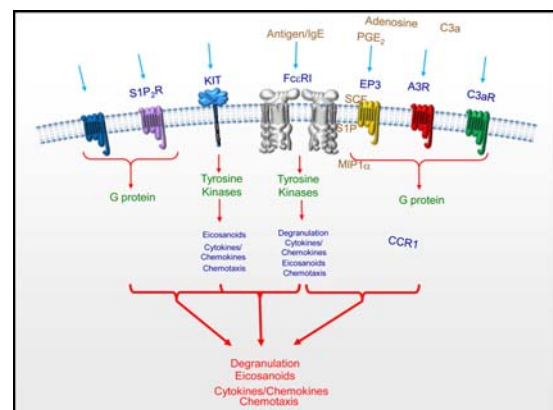
During a severe anaphylactic reaction, allergen induced cross linking of IgE binding sites on mast

cells is followed by an explosive release of granular mediators.<sup>3</sup> In addition, activated mast cells release newly synthesized membrane derived (lipid) mediators of allergic reactions into the extracellular space. Blood basophils also participate in allergic and other inflammatory reactions in the same way as mast cells.<sup>4</sup>

The capacity of mast cells and basophil to release mediators of anaphylaxis in response to cell activation, also termed releasability, depends on a number of different factors, including the primary underlying disease, number and type of (pre) activated receptors and signaling cascades, and the genetic background.<sup>5</sup> The severity of an anaphylactic reaction is determined by additional factors, including the numbers of mast cells (and basophils) involved in the reaction, presence and type of allergen, amount and type of IgE, presence of comorbidities, the local microenvironment, and the cytokine and chemokine networks.<sup>6</sup>



**Figure 1.** Mast cell mediators and pathways in inflammatory and immune responses to allergenic and pathogenic stimuli.



**Figure 2.** Activation of mast cells following FcεRI aggregation and the ability of KIT and GPCRs to modify these responses.

### Pathogenesis

Mutations in kinases (particularly in the tyrosine kinase Kit) and in enzymes and receptors (JAK2, PDGFR $\alpha$ , RASGRP4, Src-kinases, c-Cbl-encoded E3 ligase, histamine H4 receptor) which are

crucially involved in the regulation of mast cell activity have been identified as necessary to establish a clonal mast cell population, but other abnormalities yet to be determined must be added for the development of a clinically symptomatic

disease.<sup>7</sup> The observations that the same KIT mutation (e.g. D816V) can be associated with both good prognosis as well as progression to advanced disease<sup>8</sup> and that the D816V mutation has also been detected in healthy subjects<sup>9</sup> highlight the potential role of other factors in determining the progression/outcome of the disease. Recent genetic findings suggest that the clinically different subtypes of MCAD [encompassing systemic mastocytosis (SM), mast cell leukemia (MCL), and mast cell activation syndrome (MCAS)] should be more accurately regarded as varying presentations

of a common generic root process of mast cell dysfunction than as distinct diseases.<sup>10</sup>

**Classification of mast cell activation disease**

Mast cell activation disease (MCAD) denotes a collection of disorders characterized by accumulation of pathological mast cells in potentially any or all organs and tissues and/or aberrant release of variable subsets of mast cell mediators. MCAD includes: Mastocytosis, mast cell activation syndrome and mast cell leukemia.<sup>11</sup> The criteria proposed to define mast cell activation disease shown in table (1).<sup>12</sup>

**Table (1):** Criteria proposed to define mast cell activation disease.<sup>12</sup>

<b>Criteria to define mast cell activation syndrome</b>	<b>WHO criteria to define systemic mastocytosis</b>
<p><b>Major criteria</b></p> <ol style="list-style-type: none"> <li>1. Multifocal or disseminated dense infiltrates of mast cells in bone marrow biopsies and/or in sections of other extracutaneous organ(s) (e.g., gastrointestinal tract biopsies; CD117-, tryptase- and CD25-stained)</li> <li>2. Unique constellation of clinical complaints as a result of a pathologically increased mast cell activity (mast cell mediator release syndrome)</li> </ol> <p><b>Minor criteria</b></p> <ol style="list-style-type: none"> <li>1. Mast cells in bone marrow or other extracutaneous organ(s) show an abnormal morphology (&gt;25%) in bone marrow smears or in histologies</li> <li>2. Mast cells in bone marrow express CD2 and/or CD25</li> <li>3. Detection of genetic changes in mast cells from blood, bone marrow or extracutaneous organs for which an impact on the state of activity of affected mast cells in terms of an increased activity has been proved.</li> <li>4. Evidence of a pathologically increased release of mast cell mediators by determination of the content of <ul style="list-style-type: none"> <li>• tryptase in blood</li> <li>• N-methylhistamine in urine</li> <li>• heparin in blood</li> <li>• chromogranin A in blood</li> <li>• other mast cell-specific mediators (e.g., leukotrienes, prostaglandin D<sub>2</sub>)</li> </ul> </li> </ol>	<p><b>Major criterion</b></p> <p>Multifocal dense infiltrates of mast cells (&gt;15 mast cells in aggregates) in bone marrow biopsies and/or in sections of other extracutaneous organ(s) (CD117-, tryptase- and CD25-stained)</p> <p><b>Minor criteria</b></p> <ol style="list-style-type: none"> <li>1. Mast cells in bone marrow or other extracutaneous organ(s) show an abnormal morphology (&gt;25%) in bone marrow smears or in histologies</li> <li>2. Mast cells in bone marrow express CD2 and/or CD25</li> <li>3. c-kit mutation in tyrosine kinase at codon 816 in mast cells in extracutaneous organ(s)</li> <li>4. Serum total tryptase &gt;20 ng/ml (does not apply in patients who have associated hematologic non-mast-cell lineage disease)</li> </ol>

The diagnosis *mast cell activation syndrome* is made if both major criteria or the second criterion and at least one minor criterion are fulfilled. According to the WHO criteria, the diagnosis *systemic mastocytosis* is established if the major criterion and at least one minor criterion or at least three minor criteria are fulfilled.

**I. Mastocytosis**

Mastocytosis is a neoplastic disease involving mast cells (MC) and their CD34+ progenitors. Symptoms in mastocytosis are caused by biological mediators released from MC and/or the infiltration of neoplastic MC in various organs, the skin and the bone marrow being predominantly involved. A WHO consensus classification for mastocytosis

exists, which is widely accepted and includes three major categories: (1) Cutaneous mastocytosis (CM), a benign disease in which MC infiltration is confined to the skin, is preferentially seen in young children and exhibits a marked tendency to regress spontaneously. (2) Systemic mastocytosis (SM) which is commonly diagnosed in adults and includes four major subtypes: (i) indolent SM (ISM,

the most common form involving mainly skin and bone marrow); (ii) a unique subcategory termed SM with an associated non-mast cell clonal hematological disease (SM-AHNMD); (iii) aggressive SM usually presenting without skin lesions, and (iv) MC leukemia, probably representing the rarest variant of human leukemias. (3) The extremely rare localized extracutaneous MC neoplasms, either presenting as malignancy (MC sarcoma) or as benign tumor termed extracutaneous mastocytoma.<sup>13</sup>

Telangiectasia macularis eruptiva perstans (TMEP) is a rare form of cutaneous mastocytosis; in which telangiectasia occur together with the rash.<sup>14</sup>

### Presentation

#### **Possible triggers for mastocytosis symptoms:**

Physical stimuli, such as heat, cold, friction, sunlight, fatigue, exercise or fever, emotional stimuli, such as stress, certain foods, such as cheese, spices, shellfish, food preservatives, flavorings and colorings, monosodium glutamate, and environmental toxins, such as perfumes, pesticides, insect bites, jelly fish stings, snake bites, infection (bacterial, fungal or viral) and drugs, such as alcohol, anesthetic agents, dextran, aspirin and non-steroidal anti-inflammatory drugs (NSAIDs), antibiotics, opioids, thiamine, quinine, gallamine, procaine, some radiographic dyes, polymyxin B, scopolamine, and tubocurarine.<sup>15,16</sup>

#### **Cutaneous mastocytosis**

##### *Urticaria pigmentosa:*

The rash comprises light brown, itchy, raised patches - on any part of the body. The lesions blister when rubbed (Darier's sign) and become red, swollen and itchy. This confirms the presence of mastocytosis. Rarely, anaphylactic reactions can occur after mechanical/thermal stimulation of skin lesions. Dermatographism may be found on unaffected skin.<sup>16</sup> It usually affects infants from a few months of age. The lesions can persist and gradually increase in number for several months or years. Symptoms gradually improve as the child gets older, and the condition usually disappears by puberty. The younger the patient and the smaller the number of the lesions, the higher is the probability of spontaneous remission. An adult onset increases the risk of systemic involvement and persistence.<sup>14</sup>

##### *Diffuse cutaneous mastocytosis:*

This usually occurs in the first year of life. The rash is very itchy, with generalized yellowish, thickened skin. Blisters are large, sometimes hemorrhagic, and occur spontaneously or following mild trauma.

With more extensive skin involvement, systemic symptoms are more likely. These include flushing, headache, palpitations, abdominal pain, diarrhea, dyspnea, wheezing, syncope, hypotensive shock and death. Early onset of blisters worsens the prognosis.<sup>15</sup>

##### *Mastocytoma of the skin:*

This is a macular, papular or nodular lesion of yellow, brown or reddish colour.<sup>15</sup>

#### **Systemic mastocytosis**

Patients may present with "inexplicable" symptoms related to mast cell mediator release, such as vascular instability, anaphylactic shock, flushing, diarrhea and headache (sometimes without skin lesions). There is a wide range of symptoms and a variety of triggers.<sup>15-18</sup> Systemic mastocytosis is now classified as a myeloproliferative neoplasm.<sup>19</sup> Manifestations include involvement of the skin in the form of facial flushing (may be pruritic or burning) and urticaria pigmentosa, gastrointestinal manifestations as abdominal pain, diarrhea or steatorrhea (due to malabsorption or altered motility), nausea and vomiting, hyperacidity, dyspepsia and peptic ulcers, hepatosplenomegaly or splenomegaly, cardiovascular manifestations as syncope, hypotension or anaphylactic shock,<sup>17</sup> hematological manifestations and bone marrow affection in the form of anemia or other cytopenias. Other manifestations may include hypersplenism, lymphadenopathy, fractures (if bone marrow is involved) and rarely, a bleeding disorder due to heparin-like anticoagulant.<sup>18</sup> Respiratory affection in the form of bronchospasm, nasal congestion and upper pharyngeal symptoms<sup>17,20</sup> and neurological manifestations presented by headache and peripheral neuropathy are also reported.<sup>17</sup>

#### **Localized mastocytosis**

Mastocytoma is a benign tumor with uniform growth and mast cell sarcoma is a locally destructive tumour.<sup>15</sup>

## **II. Mast cell activation syndrome (MCAS)**

Mast cell activation syndrome (MCAS) presents a complex clinical picture of multiple mast cell mediator-induced symptoms, failure to meet the WHO criteria for diagnosis of SM and exclusion of relevant differential diagnoses.<sup>10,12</sup> MCAS is characterized by the accumulation of genetically altered mast cells and/or abnormal release of mast cell mediators, affecting functions in potentially every organ system, particularly the skin, gastrointestinal tract, and cardiovascular and

nervous systems. Investigations are usually normal.<sup>10</sup>

Patients experience many of the same symptoms as with mastocytosis. Chronic mast cell activation can be difficult to diagnose, especially when symptoms are mild or atypical.<sup>21</sup> The use of antihistamines and mast cell membrane-stabilizing drugs with symptomatic treatment is often effective.<sup>11</sup>

MCA-related symptoms may be mild, moderate, severe, or even life-threatening. The severity of MCAS depends on a number of different factors, including genetic predisposition, the number and releasability of mast cells involved in the reaction, the type of allergen, presence of specific IgE, and presence of certain comorbidities. In severe reactions, MCA can be documented by a substantial increase in the serum tryptase level above baseline. When symptoms are recurrent, are accompanied by an increase in mast cell-derived mediators in biological fluids, and are responsive to treatment with mast cell-stabilizing or mediator-targeting drugs, the diagnosis of mast cell activation syndrome (MCAS) is appropriate. Based on the underlying condition, these patients can further be classified into i) primary MCAS where *KIT*-mutated, clonal mast cells are detected, ii) secondary MCAS where an underlying inflammatory disease, often in the form of an IgE-dependent allergy, but no *KIT*-mutated mast cells, is found, and iii) idiopathic MCAS, where neither an allergy or other underlying disease, nor *KIT*-mutated mast cells are detectable (Table 2). It is important to note that in many patients with MCAS, several different factors act together to lead to severe or even life-threatening anaphylaxis.<sup>22</sup>

The term MCAS should be applied when i) clinical signs of severe recurrent (or chronic) systemic MCA are present, ii) involvement of mast cells can be documented by biochemical measurements. An increase in serum tryptase to at least 20% above baseline + additional 2 ng/ml (absolute) measured during or after (within 4-12 h) a clinical episode(s), and iii) the symptoms respond to therapy with mast cell-stabilizing agents or drugs directed against mast cell mediator production, mediator release, or mediator effects. All three criteria should be fulfilled to establish the diagnosis of MCAS.<sup>23</sup>

**Presentation**

MCA-related symptoms range from mild headache or abdominal cramping to severe or even life-threatening anaphylaxis (Table 3). These symptoms are caused by a number of different vasoactive and proinflammatory mediators that are released from MC when these cells are activated by an allergen via IgE and IgE receptors, or other trigger(s). Correspondingly, the severity of MCA correlates with the amount and type of mediators released from mast cells during an anaphylactic reaction. Well-recognized symptoms of immediate-type allergy, suggestive of systemic MCA, include acute urticaria, flushing, pruritus, headache, abdominal cramping and diarrhea, respiratory symptoms, and hypotension (Table 3).<sup>22</sup>

MCA can be classified into severe and less severe forms, into acute, episodic, and chronic variants, and into systemic and local entities (Table 4).<sup>22</sup>

**Table 2.** Variants of mast cell activation syndromes (MCAS) and diagnostic features.<sup>23</sup>

<b>MCAS variant</b>	<b>Discriminating/diagnostic features</b>
Primary MCAS	<i>KIT</i> D816V-mutated clonal mast cells are found (usually these mast cells express CD25)
Secondary MCAS	An underlying Allergy or Atopic Disorder inducing MCA and thus MCAS is diagnosed, but no clonal mast cells are detectable
Idiopathic MCAS	MCAS criteria are fulfilled, but no underlying reactive disease, no allergen-specific IgE, and no clonal mast cells are detectable

**Table 3.** Clinical symptoms typically found in patients suffering from mast cell activation (MCA) and their impact in the evaluation of MCA syndromes (MCAS).<sup>22</sup>

Symptom(s)	Diagnostic impact in the evaluation of severe MCA (= suspected MCA syndrome = MCAS)
Hypotension ± shock	Pathognomonic key finding in MCAS (other underlying diseases that could explain hypotension need to be excluded)
Tachycardia	Tachycardia usually accompanies hypotension in MCAS
Diarrhea	Usually accompanied by systemic symptoms of MCAS; in the absence of these, the diagnosis remains uncertain
Abdominal cramping	Usually accompanied by systemic symptoms of MCAS; in the absence of these, the diagnosis remains uncertain
Nausea	Usually accompanied by systemic symptoms of MCAS; in the absence of these, the diagnosis remains uncertain
Flushing	Severe flushing may be an indicator of MCAS; in these cases; flushing is often accompanied by systemic symptoms
Pruritus	Severe pruritus may be an indicator of MCAS; in these cases; flushing is often accompanied by systemic symptoms
Acute urticaria	Severe acute urticaria may be an indicator of MCAS; in these cases, systemic symptoms are usually found
Angioedema	Severe angioedema may be an indicator of MCAS and then is usually accompanied by systemic symptoms
Nasal congestion	Diagnostic only in the context of other MCAS-related symptoms and the presence of other MCAS criteria
Wheezing	Diagnostic only in the context of other MCAS-related symptoms and the presence of other MCAS criteria
Headache	Diagnostic only in the context of other MCAS-related symptoms and the presence of other MCAS criteria
Neurologic symptoms	Diagnostic only in the context of other MCAS-related symptoms and the presence of other MCAS criteria
Fatigue	Diagnostic only in the context of other MCAS-related symptoms and the presence of other MCAS criteria

**Table 4.** Proposed variants of mast cell activation (MCA).<sup>22</sup>

Variants	Indicator/criterion
<b>Severity</b>	
Mild MCA	No therapy required
Moderate MCA	Drug therapy required, but no need for hospitalization
Severe MCA	Hospitalization required
<b>Organ system involvement</b>	
Local MCA	Restricted to one organ, usually a local reaction
Systemic MCA	Multiorgan involvement (in severe forms: increase in serum tryptase found)
<b>Frequency</b>	
Acute MCA	Symptom(s) recorded once
Episodic MCA	Recurrent symptoms
Chronic MCA	Persistent symptoms

Life threatening MCA may occur when the burden of mast cells is high and/or these cells are in an hyperactivated state.<sup>22</sup> Whereas the underlying

disease may be a primary mast cell disease, often presenting with excessive numbers of mast cells, or an IgE-dependent allergy, resulting in IgE-

dependent release of allergic mediators from mast cells, the coexistence of both may represent a clinically serious, often life-threatening, situation.<sup>24</sup> In addition, other comorbidities may be present that influence mast cell releasability through cytokine exposure, the numbers of mast cells through KIT ligand exposure, or leukocyte activation triggered by chemokine effects. Some of the comorbidities represent classical combinations representing a high-risk situation for the occurrence of life-threatening MCA (anaphylaxis). One typical example is the presence of an allergy against hymenoptera venom(s) in patients with mastocytosis. In these patients, insect stings can lead to extremely severe reactions, and cases of death have been reported in the literature.<sup>25,26</sup> Another high-risk situation is the combination of food allergy and mastocytosis. IgE-dependent allergy against inhaled allergens and a coexisting severe bronchial disorder, for example a chronic bronchial infection, is another example. In all these situations, severe reactions need to be addressed immediately and often result in hospitalization. To address all these high-risk conditions in a prophylactic manner, patients are advised to take continuous (prophylactic) antimediator-type drugs, to carry additional emergency drugs (glucocorticosteroids, epinephrine self-injector) with them, and to self-apply these drug on demand to bridge the time until the emergency team will arrive and bring the situation under control.<sup>22</sup>

### III. Mast cell leukemia

A rare variant of MCAD is defined by increased numbers of mast cells in bone marrow smears ( $\geq 20\%$ ) and by circulating mast cells.<sup>27</sup> Patients typically suffer from rapidly progressive organopathy involving the liver, bone marrow and other organs. The bone marrow typically shows a diffuse, dense infiltration with mast cells. In typical MCL, mast cells account for more than 10% of blood leukocytes. In a smaller group of patients, pancytopenia occurs and mast cells account for less than 10% (aleukemic variant of MCL). The prognosis in MCL is poor. Most patients survive less than 1 year and respond poorly to cytoreductive drugs or chemotherapy.<sup>11</sup>

#### Clinical Diagnosis

MCAD is first suspected on clinical grounds, based on recognition of compatible mast cell mediator-related symptoms and, in some, identification of typical skin lesions. The clinical presentation of MCAD is very diverse, since due to both the widespread distribution of mast cells and the great heterogeneity of aberrant mediator expression

patterns, symptoms can occur in virtually all organs and tissues.<sup>30</sup> Moreover, symptoms often occur in a temporally staggered fashion, waxing and waning over years to decades. Symptoms often initially manifest during adolescence or even childhood or infancy but are recognized only in retrospect as MCAD-related. Clinical features and courses vary greatly and range from very indolent with normal life expectancy to highly aggressive with reduced survival times.<sup>11</sup>

In addition to the detection of the characteristic clinical constellation of findings, it must be investigated whether levels of the mast cell-specific mediators tryptase, histamine, and heparin are elevated in the blood, whether the excretion of the histamine metabolite methylhistamine into the urine is increased, and whether mast cell activity-related eosinophilia, basophilia or monocytosis in the blood can be observed. Other useful markers fairly specific to mast cells include serum chromogranin A (in the absence of cardiac and renal failure, neuroendocrine cancer, and proton pump inhibitor use) and serum and urinary leukotriene and prostaglandin isoforms (e.g., leukotriene E<sub>4</sub>, prostaglandin D<sub>2</sub>, and prostaglandin 9 $\alpha$ , 11 $\beta$ PGF<sub>2</sub>). Together with a characteristic clinical presentation, abnormal markers can be of diagnostic, therapeutic and prognostic relevance.<sup>11</sup> Marrow biopsy and immunohistochemical analysis of the specimen may permit the classification of the mast cell activation disease as SM defined by the WHO criteria or as MCAS<sup>12</sup> (Table 1).

After clinical diagnosis, a bone marrow biopsy is usually recommended because based on current information it cannot be predicted whether the genetic alterations inducing pathological mast cell activity in affected mast cells have not also induced disturbances in hematopoietic non-mast cell lineages. SM due to codon 816 mutations has been shown to be associated with myeloid neoplasms (and, less frequently, with B-cell neoplasms) frequently enough to warrant routine marrow biopsy when SM is suspected (e.g., serum tryptase elevation per the WHO criteria, frequent unprovoked anaphylactoid events).<sup>11</sup>

#### Differential diagnosis (table 5)

#### Treatment of mast cell activation diseases

The cornerstone of therapy is avoidance of identifiable triggers for mast cell degranulation such as animal venoms, extremes of temperature, mechanical irritation, alcohol, or medications (e.g., aspirin, radiocontrast agents, certain anesthetic agents). Individual patients may have variable

tolerance patterns and avoidance lists, but it also is not uncommon to have no identifiable, reliable triggers. Drug treatment of MCAD patients is highly individualized (Table 6).<sup>11</sup>

First hints of success with any given therapy are usually seen within 4 weeks once suitable dosing has been achieved. If symptoms are resistant to therapy, as a next therapeutic step toward reducing mast cell activity and thereby decreasing mediator release, treatment with prednisone, cyclosporine (cyclosporine A), low dose methotrexate or azathioprine can be considered.<sup>12</sup> Recently, anti-IgE treatment with the humanized murine monoclonal antibody omalizumab has alleviated high intensity symptoms of MCAD.<sup>29</sup>

Immunotherapy should be considered if anaphylaxis is provoked by a known allergy, especially hymenoptera venom.<sup>30</sup> Potential

therapeutic options are interferon- $\alpha$  and 2-chlorodeoxy-adenosine (2-CdA, cladribine). Interferon- $\alpha$  is frequently combined with prednisone and is commonly used as first-line cytoreductive therapy for aggressive SM. 2-Chlorodeoxyadenosine (2-CdA) is generally reserved for last choice treatment of patients with aggressive SM who are either refractory or intolerant to interferon- $\alpha$ . Patients who fail interferon- $\alpha$  and 2-CdA therapy are candidates for experimental drugs. Polychemotherapy including intensive induction regimens of the kind used in treating acute myeloid leukemia, as well as high-dose therapy with stem cell rescue, represent investigational approaches restricted to rare, selected patients.<sup>11</sup>

**Table 5.** Major differential diagnoses in patients with suspected mast cell activation syndrome (MCAS).<sup>22</sup>

#### **Cardiovascular**

- Myocardial infarction
- Endocarditis/endomyocarditis
- Aortic stenosis with syncope
- Pulmonary infarction

#### **Endocrinologic**

- Acute hypothyroidism
- Acute hypoglycemia
- Adrenal insufficiency
- Hypopituitarism

#### **Gastrointestinal Disorders (with Diarrhea + Dehydration)**

- Acute inflammatory bowel disease
- VIP-secreting tumor (vipoma)\*
- Acute episodes of morbus crohn or colitis ulcerosa
- Food intoxication

#### **Infectious Diseases**

- Severe bacterial or viral infections  $\pm$  septic shock
- Acute gastrointestinal infection with dehydration
- Acute encephalitis/meningitis
- Acute parasitic diseases (e.g. acute Chagas disease)

#### **Neurologic/Central Nervous System (CNS) Disorders**

- Epilepsy
- CNS tumors
- Other CNS diseases
- Intoxication
- Psychiatric conditions

#### **Skin Diseases**

- Hereditary or acquired angioedema
- Pemphigus vulgaris
- Acute lupus erythematosus
- Acute toxic dermatoses

#### **Hematologic – Acute Anemia $\pm$ Hypovolemic Shock**

- Acute gastrointestinal bleeding
- Massive hypermenorrhea

#### **Drug-induced Side Effects**

- Drug-induced hypoglycemia
- Drug-induced hypotension
- Drug-induced diarrhea
- Drug-Induced CNS damage

\* VIP, vasoactive intestinal peptide.

**Table 6.** Treatment options for mast cell activation disease.<sup>11</sup>

<p><b>Basic therapy (continuous oral combination therapy to reduce mast cell activity)</b></p>	<p><b>H<sub>1</sub>-histamine receptor antagonist</b> (to block activating H<sub>1</sub>-histamine receptors on mast cells; to antagonize H<sub>1</sub>-histamine receptor-mediated symptoms)  <b>H<sub>2</sub>- histamine receptor antagonist</b> (to block activating H<sub>2</sub>-histamine receptors on mast cells; to antagonize H<sub>2</sub>-histamine receptor-mediated symptoms)  <b>Cromolyn sodium</b> (stabilizing mast cells)  <b>Slow-release Vitamin C</b> (increased degranulation of histamine; inhibition of mast cell degranulation; not more than 750 mg/day)                      If necessary, <b>ketotifen</b> to stabilize mast cells and to block activating H<sub>1</sub>-histamine receptors on mast cells</p>
<p><b>Symptomatic treatment options</b> (orally as needed)</p>	<p><b>Headache:</b> paracetamol; metamizole; flupirtine  <b>Diarrhea:</b> colestyramine; nystatin; montelukast; 5-HT<sub>3</sub> receptor inhibitors (such as ondansetron); incremental doses (50-350 mg/day; extreme caution because of the possibility to induce mast cell degranulation) of acetylsalicylic acid; (in steps test each drug for 5 days until improvement of diarrhea)  <b>Colicky abdominal pain:</b> metamizole; butylscopolamine  <b>Nausea:</b> metoclopramide; dimenhydrinate; 5-HT<sub>3</sub> receptor inhibitors; icatibant  <b>Respiratory symptoms</b> (mainly increased production of viscous mucus and obstruction with compulsive throat clearing): montelukast; urgent: short-acting β-sympathomimetic  <b>Gastric complaints:</b> proton pump inhibitors (de-escalating dose finding)  <b>Osteoporosis, osteolysis, bone pain:</b> biphosphonates (vitamin D plus calcium application is second-line treatment in MCAD patients because of limited reported success and an increased risk for developing kidney and ureteric stones)  <b>Non-cardiac chest pain:</b> when needed, additional dose of a H<sub>2</sub>-histamine receptor antagonist; also, proton pump inhibitors for proven gastroesophageal reflux  <b>Tachycardia:</b> verapamil; AT1-receptor antagonists; ivabradin  <b>Neuropathic pain and paresthesia:</b> α-lipoic acid  <b>Interstitial cystitis:</b> pentosan, amphetamines  <b>Sleep-onset insomnia/sleep-maintenance insomnia:</b> triazolam/oxazepam  <b>Conjunctivitis:</b> exclusion of a secondary disease; otherwise preservative-free eye drops with glucocorticoids for brief courses  <b>Hypercholesterolemia:</b> (does not depend on the composition of the diet) therapeutic trial with HMG-CoA reductase inhibitors (frequently ineffective)  <b>Elevated prostaglandin levels, persistent flushing:</b> incremental doses of acetylsalicylic acid (50-350 mg/day; extreme caution because of the possibility to induce mast cell degranulation)</p>

**Conclusion**

Although mast cells have a sufficient repertoire of bioactive mediators to mount effective innate and adaptive defense mechanisms against invading microorganisms, these same mediators can adversely affect surrounding tissues in the host, resulting in autoimmune disease as well as allergic disorders. MCAD comprises disorders affecting functions in potentially every organ system by abnormal release of mediators from and/or accumulation of genetically altered mast cells. Effective therapy often consists simply of antihistamines and mast cell membrane-stabilizing compounds supplemented with medications targeted at specific symptoms and complications.

**REFERENCES**

1. **GILFILLAN AM, BEAVEN MA.** Regulation of mast cell responses in health and disease. *Crit Rev Immunol* 2011;31(6):475-529.
2. **GALLI SJ, TSAI M.** Mast cells in allergy and infection: versatile effector and regulatory cells in innate and adaptive immunity. *Eur J Immunol* 2010;40:1843-51.
3. **GALLI SJ, TSAI M.** IgE and mast cells in allergic disease. *Nat Med* 2013;18:693-704.
4. **SCHWARTZ LB.** Mast cells and basophils. *Clin Allergy Immunol* 2002;16:3-42.
5. **HAVARD S, SCOLA AM, KAY LJ, ISHMAEL SS, MACGLASHAN DW, PEACHELL PT.** Characterization of syk expression in human lung mast cells: relationship with function. *Clin Exp Allergy* 2011; 41: 378-88.



6. **KOMAI-KOMA M, BROMBACHER F, PUSHPARAJ PN, ARENDSE B, MCSHARRY C, ALEXANDER J, ET AL.** Interleukin-33 amplifies IgE synthesis and triggers mast cell degranulation via interleukin-4 in naïve mice. *Allergy* 2012;67:1118-26.
7. **MOLDERINGS GJ, MEIS K, KOLCK UW, HOMANN J, FRIELING T.** Comparative analysis of mutation of tyrosine kinase kit in mast cells from patients with systemic mast cell activation syndrome and healthy subjects. *Immunogenetics* 2010;62:721-7.
8. **GARCIA-MONTERO AC, JARA-ACEVEDO M, TEODOSIO C, SANCHEZ ML, NUNEZ R, PRADOS A, ET AL.** KIT mutation in mast cells and other bone marrow hematopoietic cell lineages in systemic mast cell disorders: a prospective study of the Spanish Network on Mastocytosis (REMA) in a series of 113 patients. *Blood* 2006; 108:2366-72.
9. **LAWLEY W, HIRD H, MALLINDER P, MCKENNA S, HARGADON B, MURRAY A, ET AL.** Detection of an activating c-kit mutation by real-time PCR in patients with anaphylaxis. *Mutation Res* 2005;572:1-13.
10. **AKIN C, VALENT P, METCALFE DD.** Mast cell activation syndrome: Proposed diagnostic criteria. *J Allergy Clin Immunol* 2010;126:1099-104.
11. **MOLDERINGS GJ, BRETTNER S, HOMANN J, AFRIN LB.** Mast cell activation disease: A concise practical guide for diagnostic workup and therapeutic options. *J Hematol Oncol* 2011;4:10-7.
12. **VALENT P, HORNY HP, ESCRIBANO L, LONGLEY BJ, LI CY, SCHWARTZ LB, ET AL.** Diagnostic criteria and classification of mastocytosis: a consensus proposal. *Leuk Res* 2001;25:603-25.
13. **HORNY HP, SOTLAR K, VALENT P.** Mastocytosis state of the art. *Pathobiology* 2007;74(2):121-32.
14. **VANNORSDELL EJ, COLLINS JA, CHEN QC, SARAI G, BAER MR.** Symptomatic response to imatinib mesylate in cutaneous mastocytosis associated with chronic myelomonocytic leukemia. *Curr Oncol* 2013;20(4):e349-53.
15. **SILVA I, CARVALHO S, PINTO PL, MACHADO S, ROSADO PINTO J.** Mastocytosis: a rare case of anaphylaxis in paediatric age and literature review. *Allergol Immunopathol (Madr)* 2008;36(3):154-63.
16. **HOGAN DJ, MASTRODOMENICO CM, MCCALMONT T, VINSON RP, ELENITSAS R, GELFAND JM, ET AL.** Mastocytosis, overview, predominantly of skin manifestations – useful images, 2010. Available at: <http://emedicine.medscape.com/article/1057932-overview>, Updated August 2013.
17. **LEE JK, WHITAKER SJ, ENNS RA, ZETLER P.** Gastrointestinal manifestations of systemic mastocytosis. *World J Gastroenterol* 2008;14(45):7005-8.
18. **KOENIG M, MOREL J, REYNAUD J, VARVAT C, CATHÉBRAS P.** An unusual cause of spontaneous bleeding in the intensive care unit mastocytosis: A case report. *Cases J* 2008;1(1):100.
19. **KRISHNAN K, JAISHANKAR D, DAVIS TH, TALAVERA F, SACHER RA, MCKENNA R, ET AL.** Mastocytosis, Systemic, 2010. Available at: <http://emedicine.medscape.com/article/203948-overview>. Cited on August 20, 2013.
20. **TAMHANKAR PM, SUVARNA J, DESHMUKH GT.** Cutaneous mastocytosis. Getting beneath the skin of the issue: A case report. *Cases J* 2009;2(1):69.
21. **VALENT P, HORNY HP, TRIGGIANI M, AROCK M.** Clinical and laboratory parameters of mast cell activation as basis for the formulation of diagnostic criteria. *Int Arch Allergy Immunol* 2011;126(6):1099-104.
22. **VALENT P.** Mast cell activation syndromes: definition and classification. *Allergy* 2013;68(4):417-24.
23. **VALENT P, AKIN C, AROCK M, BROCKOW K, BUTTERFIELD JH, CARTER MC, ET AL.** Definitions, criteria and global classification of mast cell disorders with special reference to mast cell activation syndromes: a consensus proposal. *Int Arch Allergy Immunol* 2012;157:215-25.
24. **METCALFE DD, SCHWARTZ LB.** Assessing anaphylactic risk? Consider mast cell clonality. *J Allergy Clin Immunol* 2009;123:687-88.
25. **WIMAZAL F, GEIBLER P, SHNAWA P, SPERR WR, VALENT P.** Severe life threatening or disabling anaphylaxis in patients with systemic mastocytosis: A single center experience. *Int Arch Allergy Immunol* 2012;157:399-405.
26. **BONADONNA P, ZANOTTI R, PAGANI M, CARUSO B, PERBELLINI O, COLAROSSO S, ET AL.** How much specific is the association between hymenoptera venom allergy and mastocytosis? *Allergy* 2009;64:1379-82.
27. **VALENT P, AKIN C, ESCRIBANO L, FÖDINGER M, HARTMANN K, BROCKOW K, ET AL.** Standards and standardization in mastocytosis: consensus statements on diagnostics, treatment recommendations and response criteria. *Eur J Clin Invest* 2007;37:435-53
28. **HOMANN J, KOLCK UW, EHNE A, FRIELING T, RAITHEL M, MOLDERINGS GJ.** Systemic mastocytosis - definition of an internal disease. *Med Klin (Munich)* 2010;105:544-53.
29. **MOLDERINGS GJ, RAITHEL M, KRATZ F, AZEMAR M, HAENISCH B, HARZER S, ET AL.** Omalizumab treatment of systemic mast cell activation disease: experiences from four cases. *Intern Med* 2011;50:1-5.
30. **Bonadonna P, Zanotti R, Müller U.** Mastocytosis and insect venom allergy. *Curr Opin Allergy Clin Immunol* 2010;10:347-53.