

East African Medical Journal Vol. 83 No. 10 October 2006

SCHISTOSOMIASIS PRESENTING AS ACUTE APPENDICITIS

K.B. Badmos, MBBS, Senior Registrar, Department of Morbid Anatomy and Forensic Medicine, Obafemi Awolowo University Teaching Hospitals Complex, Ile-Ife, Nigeria, A.O. Komolafe, FMCPATH, Consultant Histopathologist, Department of Morbid Anatomy and Histopathology, Ladoke Akintola University of Technology Teaching Hospital, Osogbo, Nigeria and O. Rotimi, MRCPATH, Consultant Histopathologist, Department of Histopathology, Leeds General Infirmary, Leeds, UK

Request for reprints to: Dr. K.B. Badmos, Department of Morbid Anatomy and Forensic Medicine, Obafemi Awolowo University Teaching Hospitals Complex, Ile-Ife, Nigeria

SCHISTOSOMIASIS PRESENTING AS ACUTE APPENDICITIS

K.B. BADMOS, A.O. KOMOLAFE and O. ROTIMI

ABSTRACT

Background: Schistosomiasis is a chronic granulomatous inflammation that affects many systems in the body including the gastrointestinal tract. This study was carried out by reviewing all cases of schistosomal appendicitis, and documents any association with acute appendicitis.

Objective: To review all cases of schistosomal appendicitis and document any possible association with acute appendicitis.

Design: A retrospective study.

Setting: Obafemi Awolowo University Teaching Hospitals Complex, Ile-Ife, Nigeria, 1991 to 2004.

Subjects: Eight hundred and three specimen of appendicectomy were reviewed. Thirty five of them were diagnosed as schistosomal appendicitis.

Results: The involvement of the vermiform appendix by schistosomiasis found in 35/843 (4.2%) cases of all the appendicectomy specimen received in our histopathology laboratory between 1991 and 2004 shows that 23 of the cases (65.7%) had histologically proven acute appendicitis while the remaining 12 cases (34.3%) were schistosomiasis without active inflammation. The appendiceal wall oviposition is associated with submucosal fibrosis, narrowing of the lumen and subsequent acute suppurative inflammation in 17 cases while there were active granulomas with tissue eosinophilia in six cases.

Conclusion: This finding has demonstrated that though the frequency of appendix involvement is low considering the endemicity of schistosomiasis in our environment, however acute appendicitis may be caused by schistosomiasis.

INTRODUCTION

Schistosomiasis is a chronic granulomatous disease that affects many systems and organs, including the gastrointestinal system. It is seen in many parts of the world including Nigeria. Schistosomiasis of the appendix is a well-recognised disease and there have been reports from Nigeria (1,2). Some reports have implicated *haematobium* and *mansoni* species in having preference for the appendix (3,4). However,

the role of schistosomal infestation in the cause of acute appendicitis is still debatable. Over the years, a number of case reports and case series have suggested that the infestation is a cause of acute appendicitis (5-7). But the relatively low incidence of acute appendicitis as a disease in areas highly endemic for schistosomiasis has cast doubt on this assertion (1,8).

In this study, we report the clinicopathological findings of 35 cases of schistosomal appendicitis

seen at the Obafemi Awolowo University Teaching Hospitals Complex (OAUTHC), Ile-Ife, Nigeria, over the 14-year period of 1991 to 2004. The aims of this review were to document the frequency of schistosomal appendicitis in our area and the pattern of distribution with age and sex. The findings will be compared with those from other studies in other areas of the world.

MATERIALS AND METHODS

The data for the study was from the surgical pathology register of the Morbid Anatomy Department of Obafemi Awolowo University Teaching Hospitals Complex (OAUTHC), Ile-Ife. Eight hundred and forty three appendicectomy specimens were received within the study period. Thirty five of these were diagnosed as schistosomal appendicitis. The biodata of the cases were extracted from the request cards. We adapted the histopathological criteria used by Satti *et al* (7), in which the cases were divided into three groups - schistosomal obstructive acute appendicitis, schistosomal granulomatous acute appendicitis and schistosomal appendicitis with neither active granulomas nor purulent exudates. This method is based on the presence or absence of active granulomatous inflammation or purulent exudates in the lumen and/or the wall. In the presence of active granulomas in the wall, a diagnosis of schistosomal acute granulomatous appendicitis is made while the presence of purulent exudates in the wall is termed schistosomal acute obstructive appendicitis.

RESULTS

Over a period of 14 years, 843 appendices were histologically examined in the department. Thirty-five of these representing 4.15% had schistosomal appendicitis. There were 26 males and nine females (ratio 2.9:1) with an age range of 13 to 62 years and a median of 25 years. Majority of the patients, 30 (85.7%) were below 40 years and the peak incidence was in the 10-19 years age group (34.3%).

The presenting complaints (Table 1) were abdominal pains and vomiting that were seen in 28 (80%) and 12 (34.3%) patients respectively. The others were fever and altered bowel motion in seven (20%) and one (2.1%) of the cases respectively. The clinical diagnosis shows that acute appendicitis is the most frequently made diagnosis – twenty five cases. Others include three sub-acute appendicitis, three incidental appendicectomies and two suspected malignancies in the right iliac fossa.

Gross examinations of the specimen showed features of acute appendicitis with fibrinopurulent exudates in nine cases, serosa congestion in ten, thickened wall in eight and the last eight cases were grossly normal. The gross findings were not recorded in three cases. Microscopic examinations (Table 2) showed that all the appendices had schistosomal ova in the mucosa and/or different parts of the wall. The other tissue reactions include submucosal fibrosis, active granuloma formation with tissue eosinophilia, infiltrates of acute and chronic inflammatory cells.

Table 2

Correlation of clinicopathological diagnosis of 35 cases

Pathological diagnosis	Clinical diagnosis				Total (%)
	Acute appendicitis	Subacute appendicitis	Malignancy	Incidental	
Schistosomal acute obstructive appendicitis	15	-	1	1	17 (48.6)
Schistosomal acute granulomatous appendicitis	3	2	-	1	6 (17.1)
Schistosomal appendicitis without active inflammation	7	1	1	1	10 (34.3)
Total (%)	25 (71.4)	3 (8.6)	2 (5.7)	3 (8.6)	33

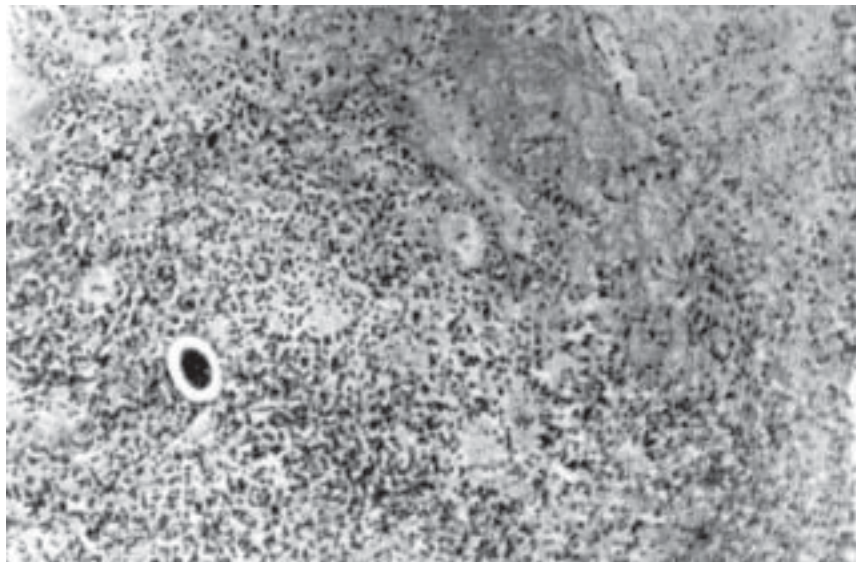
Table 1*Clinical presentation of 35 cases*

Feature	Frequency (%)
Abdominal pain	28 (80.0)
Vomiting	12 (34.3)
Fever	7 (20.0)
Altered bowel motion	1 (2.9)

Of the 34 cases, 23 (65.7%) showed evidence of recent inflammation based on Satti *et al* criteria (7). Out of these, seventeen had infiltration of the wall by acute inflammation (Figure 1) with associated peritonitis (\pm perforation) in some cases while the remaining six had evidence of active granulomatous inflammation. The first group was schistosomal acute obstructive appendicitis while the later group was schistosomal acute granulomatous appendicitis.

Figure 1

Section of the appendix showing purulent exudates within the wall and schistosomal ova. (Haematoxylin and eosin, x160)

**Figure 2**

Section shows appendix with calcified schistosomal ova, fibrosis of the wall and infiltration by eosinophils, histiocytes, and multinucleated giant cells. (Haematoxylin and eosin, x160)

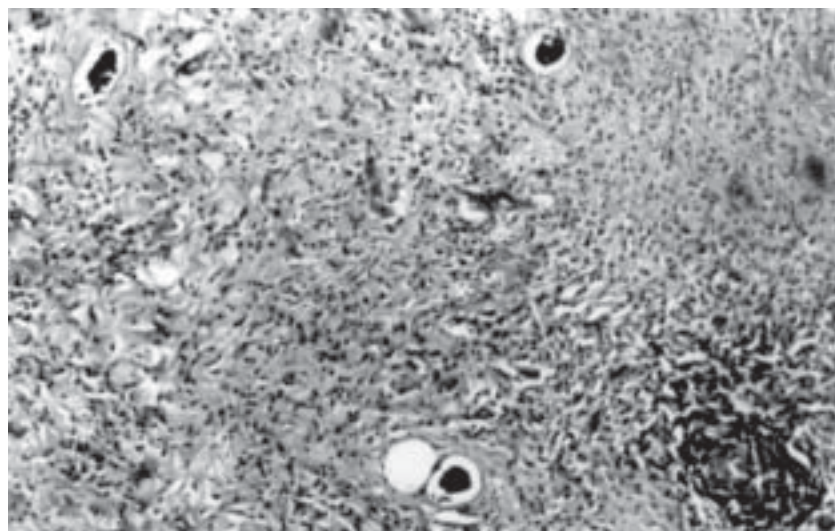


Table 3*Histopathological findings of 35 cases*

Histological finding	Frequency (%)
Ova	
Submucosa layer	7 (20.0)
Muscularis layer	4 (11.4)
Serosa layer	7 (20.0)
Mucosa and submucosa	2 (5.7)
Mucosa and muscularis layer	4 (11.4)
Submucosa and muscularis layer	8 (22.9)
Submucosa and serosa layer	2 (5.7)
Mucosa and submucosa and muscularis	1 (2.9)
Tissue reaction	
Acute suppurative inflammation	17 (48.6)
Submucosal fibrosis	7 (20.0)
Tissue eosinophilia	6 (17.1)
Granulomatous inflammation	13 (37.1)
Chronic inflammation	6 (17.1)
Submucosal lymphoid follicle	
Hyperplasia	7 (20.0)

The remaining twelve cases of schistosomal appendicitis without active inflammation (Figure 2) had chronic inflammation and old granulomas with areas of dystrophic calcification in five and seven cases respectively. The two cases of suspected malignancies were diagnosed as schistosomal acute obstructive appendicitis and schistosomal appendicitis without active inflammation, and no malignancy was seen. There were seven false-positive cases of clinically diagnosed acute appendicitis (Table 3).

DISCUSSION

Schistosomiasis is endemic in many parts of Nigeria. The incidence of schistosomal appendicitis from this study is 4.15% and this is much higher than reported by Ojo *et al* (2), and Adebamowo *et al* (1), both in the southwestern part of Nigeria with values of 0.9% and 2.4% respectively (1,2). A much earlier report by Attah and Banigo in Ibadan quoted a figure of 9% (9). One plausible reason for the initial fall is the impact of widespread availability and treatment with effective drugs in the late 1970's and early 1980's. And this recent rise could be the effects of severe economic depression from the late 1980's on the provision of social and medical amenities in Nigeria.

The peak incidence was in the 10-19 years age group and this is similar to what Duvie *et al* (10) reported, although this is lower when compared to the peak age of incidence of acute appendicitis seen in the third decade generally in this environment (11).

A critical appraisal of the association between schistosomiasis and acute appendicitis from our histopathological review showed that seventeen cases had infiltration of the submucosal and the muscularis layer by polymorphonuclear leukocytes in addition to the presence of schistosomal ova. Variable degrees of fibrosis were noted in the wall particularly in the submucosa and serosa layers. Also, two of the cases had perforation of the appendix wall with peritonitis. The presence of schistosomal ova within the appendix wall is known to induce chronic inflammation with fibrosis although it may take weeks or years to develop with resultant narrowing of the lumen and subsequent acute appendicitis. These are the cases termed schistosomal acute obstructive appendicitis.

Most of the patients in this group are in the age range of 14-62 years with a mean of 27 years. The remaining six cases diagnosed as acute appendicitis had active granulomas with tissue eosinophilia particularly within the submucosa and muscular

layers. These granulomas are believed to be due to immune complexes around recently deposited ova, the Hoeppli – Splendore phenomenon. Thus most of these patients are usually young as seen in this report wherein the age range is from 15-25 years with a mean of 24.7 years. The last twelve cases had chronic inflammation and granulomatous inflammation with higher frequency of dystrophic calcification.

This report has not only confirmed the impression of some earlier authors that schistosomiasis can cause acute appendicitis but it should be considered as a differential diagnosis in patients who are in their second decade of life with features of acute appendicitis. Also of paramount importance is that all appendicectomy specimens should be sent for histopathological review so that patients could benefit from full investigation and treatment.

REFERENCES

1. Adebamowo C.A., Akang E.E.U., Ladipo J.K. and Ajao O.G. Schistosomiasis of the appendix. *Brit. J. Surg.* 1991; **78**: 1219-1221.
2. Ojo O.S., Udeh S.C. and Odesanmi W.O. Review of the histopathological findings in appendices removed for acute appendicitis in Nigerians. *J.R. Coll Surg. Edinb.* 1991; **36**: 245-248.
3. Smith J.H., Kamel I.A., Elwi A. and Von Lichtenberg F. A quantitative post-mortem analysis of urinary schistosomiasis in Egyptians. Pathology and pathogenesis. *Amer. J. Trop. Med. Hyg.* 1974; **23**: 1054-1071.
4. Lima J.P.R. Study of the so called ectopic lesions in schistosomal mansoni infections I: general incidence. *Revista Do Institution De Medicina Tropical de Sao Paulo.* 1962; **8**: 167-172.
5. Jones H.J.S., Ibrahim A.E.K. and Deroda J.K. Schistosomiasis of the appendix in the UK. *Brit. J. Clin. Pract.* 1997; **51**: 183.
6. Lee J.FY., Chung C.C. and Lau W.Y. A case of schistosomal appendicitis. *IJCP* 1997; **51**: 518-519.
7. Satti M.B., Tamimi D.M., Al Sohaibani M.O. and Al Quarain A. Appendicular schistosomiasis: A cause of clinical acute appendicitis? *J. Clin. Pathol.* 1987; **40**: 424-428.
8. Hodasi M. Schistosoma appendicitis. *Trop. Doct.* 1988; **18**: 105-106.
9. Attah E.B. and Banigo O.G. Schistosomal appendicitis. *Int. Surg.* 1975; **60**: 616-617.
10. Duvie S.O.A., Diffang C. and Guirguis M.N. The effects of schistosoma haematobium infestation on vermiform appendix - The Nigerian experience. *J. Trop. Med. Hyg.* 1987; **90**: 13-18.
11. Adekunle O.O. and Funmilayo J.S. Acute appendicitis in Nigeria. *J.R. Coll. Surg. Edinb.* 1986; **31**: 102-105.
12. Healy V., Keaye F.B.V. and Tucker O.N. Granulomatous appendicitis. *J. Coll. Surg. Edinb.* 2003; **1**: 286-289.