

East African Medical Journal Vol. 78 No. 8 August 2001

ORAL MANIFESTATIONS OF HIV/AIDS IN A KENYAN PROVINCIAL HOSPITAL

F.M.A. Butt, BDS, Coast Province General Hospital, Mombasa, Kenya, M.L. Chindia, BDS, MSc, FFDRCSI, Faculty of Dental Sciences, University of Nairobi, V.P. Vaghela, MBChB and K. Mandalia, MBChB, MRCPATH, Coast Province General Hospital, Mombasa, Kenya.

Request for reprints to: Dr. M. L. Chindia, Faculty of Dental Sciences, College of Health Sciences, University of Nairobi, P.O. Box 19676, Nairobi.

ORAL MANIFESTATIONS OF HIV/AIDS IN A KENYAN PROVINCIAL HOSPITAL

F.M.A. BUTT, M.L. CHINDIA, V.P. VAGHELA and K. MANDALIA

ABSTRACT

**Background:** In Kenya many patients exposed to the HIV infection present with orofacial lesions as the primary manifestations of the disease and only a few studies have been performed to document this observation.

**Objective:** To clinically evaluate and document the range and pattern of oral lesions in a group of hospitalised patients with HIV-infection.

**Design:** A prospective study.

**Setting:** Coast Province General Hospital in Mombasa, Kenya, which is the main referral institution serving a population of approximately two million people.

**Methods:** Examination of all the cases included in the study was performed according to the WHO criteria. Both male and female patients aged 16 years and above were selected. The criterion of recruitment was based on a suspicion of immunosuppression, the presence of oral manifestations and the willingness to participate in the study. Prior to the examination each patient had undergone counselling followed by two consecutive screening tests using the ELISA technique. Where indicated incisional biopsy was performed to confirm the clinical diagnosis of the relevant lesions. In collaboration with the medical team, treatment was administered as per the needs of the patient in terms of anti-fungals, antivirals or topical corticosteroids.

**Results:** Of the 61 cases, 25(41%) were males and 36(59%) females with an age range of 19 to 65 years (mean = 34.7years). While all the cases had periodontal disease, over 80% had candidiasis of the hyperplastic, erythematous and pseudomembranous types. Lymphadenopathy and angular cheilitis were each diagnosed in 27.9% of the cases; while oral Kaposi's sarcoma was seen in 13% of the patients. Other conditions seen included persistent oral ulceration (11.5%), oral hairy leukoplakia and herpes zoster each constituting 4.9%; herpes simplex, mucosal hyperpigmentation, parotomegaly and facial palsy each comprised six per cent and oral warts seen in one case. In accordance with the pattern and prevalence of oral manifestations in our study, the results were largely consistent with those documented elsewhere.

**Conclusion:** For the alleviation of the morbidity arising from the commonly occurring lesions, early detection is mandatory. Furthermore, documentation of the varied regional patterns of occurrence of these lesions may aid in the rational application of the emerging treatments.

INTRODUCTION

The years of the AIDS epidemic have taught us many lessons about oral disease hence new oral lesions have been discovered, while old diseases have appeared in new guises(1). The common manifestations of HIV are mainly of infective origin (particularly fungal, viral and mycobacterial), neoplasms (especially oral Kaposi's sarcoma and lymphomas which may be virally induced), and autoimmune disorders(2). Oral lesions are often clearly visible and several can be diagnosed on clinical features alone(3). The study of oral manifestations in HIV-infection

is of importance because oral lesions may suggest the characteristics of HIV-infection and serostatus in addition to the fact that certain lesions such as oral candidiasis and hairy leukoplakia may be predictors of the development of the HIV disease; and some of the oral lesions may result in the re-classification of HIV-infected patients from one CDC - category to another(4).

Mortality rate in patients with opportunistic infections whose HIV status is unknown is almost five times greater than in those whose HIV status is known. Oral assessment is of paramount importance in terms of the benefits of early diagnosis: it can aid in prolonging the asymptomatic

period, delay disease progression, prevent opportunistic infections with optimal maintenance of health via patient education and counselling.

Entering the second decade of the African epidemic a few reports on the clinical spectrum, prevalence, diagnostic and prognostic value of the oral manifestations of HIV-infection in the Kenyan population have been published(5,6). The purpose of the present study was to evaluate the range of oral lesions in patients exposed to the HIV-infection in an urban setting of Kenya deemed to be a high risk area with respect to the occurrence of the HIV disease and AIDS.

## MATERIALS AND METHODS

The study sample constituted 61 consecutive patients admitted within six months in 1996, at the Coast Province General Hospital, Mombasa for the management of diverse conditions and lesions in the course of the HIV disease and AIDS. The diverse conditions they presented with included disseminated tuberculosis, pneumonia, gastroenteritis and AIDS Dementia Complex. On admission each patient underwent a comprehensive medical examination (by VPV) in addition to being professionally counselled prior to being subjected to two consecutive enzyme linked immunosorbent assay (ELISA) screening tests for HIV infection. Counselling was done to educate the patient and as an important part of the psychological management of the disease.

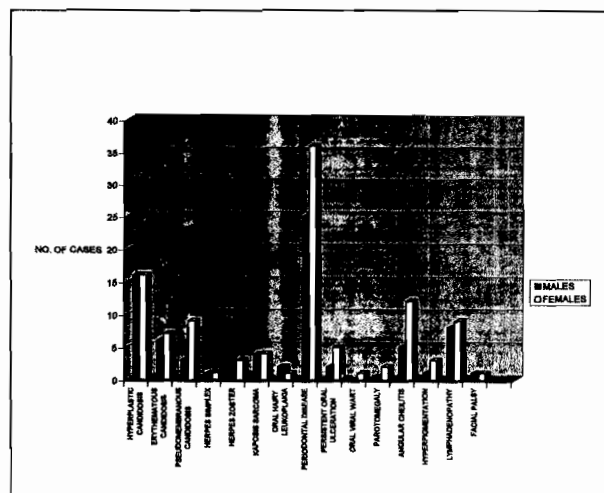
Clinical orofacial examination was performed according to the WHO criteria(7) by a dental clinician (FMAB). Both the medical and dental clinicians had been trained according to the published WHO guidelines to ensure the reproducibility of the clinical observations. Close consultation with a clinical pathologist and an oral and maxillofacial surgeon was maintained for consensus of opinion in all the observations. Where indicated, incisional biopsy and microbiological specimens were taken in order for histopathological and microbiological examination to be performed in the usual way, employing the haematoxylin and eosin stains in addition to organism culturing respectively. Thus, all the cases clinically diagnosed as manifesting oral Kaposi's sarcoma (OKS), oral hairy leukoplakia and viral warts had biopsies performed, while clinically equivocal cases of candidiasis had culturing done. All lesions encountered were clinically evaluated and recorded in specially designed charts, according to the CDC classification of patients with HIV infection: Group 1 acute HIV infection; Group 2 asymptomatic HIV infection; Group 3 persistent generalised lymphadenopathy and; Group 4 clinical symptoms of HIV infections, opportunistic infections, neoplasms and neurological disorders.

## RESULTS

Out of the 61 patients, 25 (41%) were males and 36 (59%) were females with an overall age range of 19 to 65 years and a mean age of 34.7 years. While the age range among the male patients was 22 to 65 years (mean=37.8 years.), the female age range was 19 to 55 years (mean=32.6 years). The combined gender distribution of the patients according to the age groups is presented in Figure 1.

Figure 1

Combined gender distribution of the number of patients according to the age groups



All the patients were admitted in the hospital for the management of various systemic conditions and oral manifestations associated with HIV infection, though the latter were not the primary reason for admission. Notably, six out of the sixty one patients (10%) presented with dysphagia, with resultant wasting and weight loss. Out of the total number of patients studied, 35 presented with features of chronic gastroenteritis, which included profuse watery diarrhoea with vomiting and abdominal pains over a period of greater than two months. Thirty out of the sixty one patients had respiratory tract infections, nine had been diagnosed as having pulmonary tuberculosis (PTB) evidenced by haemoptysis for more than three weeks, chronic cough for more than one month, chest pain, breathlessness with fever and night sweats. These patients had sputum-smear positive PTB and chest x-rays with consistent features. In addition, features consistent with extra-pulmonary tuberculosis were noted including TB-peritonitis, TB-meningitis and TB-retinitis. Central nervous system manifestations of HIV infection, were noted in eight patients and these comprised a history of chronic headache, confusion, loss of memory and both recent and long term cranial nerve paralysis.

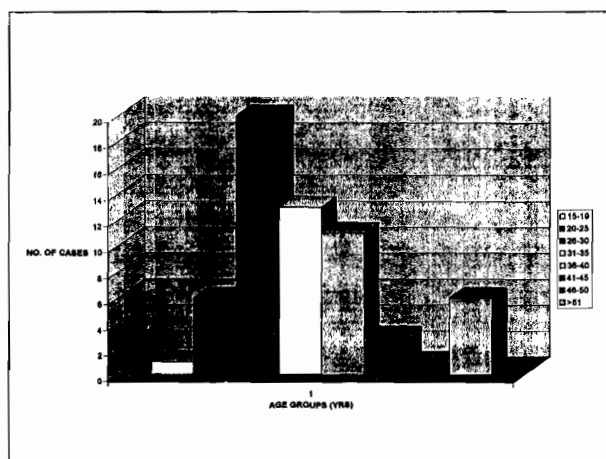
While all the patients in the study had various forms of periodontal disease (HIV gingivitis, HIV necrotising gingivitis and HIV periodontitis), over 80% of them had oral candidiasis of the hyperplastic (52.5%), erythematous (21.3%) and pseudomembranous (19.7%) types. Lymphadenopathy and angular cheilitis were each diagnosed in 27.9% of the cases and oral Kaposi's sarcoma (OKS) was seen in 13% of them. Other conditions seen included persistent oral ulceration (11.5%), oral mucosal hyperpigmentation (6.6%), herpes simplex, parotomegaly and facial palsy each comprising less than six per cent of the cases while wart-like lesions were seen in only one

patient. Persistent oral ulcerations appeared in multiple or single form and were of the minor type, which inflicted a lot of pain. Oral mucosal hyperpigmentation was mainly seen over the hard palate but its presence could not be associated with any specific cause.

According to the CDC classification most of our patients, approximately more than 80% fell in group 4 with full blown presentation of various opportunistic infections such as candidiasis, aphthous ulcers, oral hairy leukoplakia (OHL) and OKS in addition to neurological disorders. The rest were distributed in the other HIV/AIDS groups as follows: 16.4% in group 3, 3.3% in group 1 and none in group 2.

Figure 2

Distribution of all the oral lesions seen in the study population



The distribution of all the oral lesions diagnosed in this population according to gender is depicted in Figure 2. Other socio-demographic parameters evaluated in the study included the individual marital status, which established that whereas eleven of the men were either single/ divorced or widowed, 19 of the women belonged to this category. Perhaps significantly, more than twice as many self employed/unemployed women were afflicted by HIV/AIDS than men in this category. Notably, nearly 83.3% of the female and 96% of the male patients had been residing in the study area for at least ten years.

## DISCUSSION

Oral disease is common in HIV-infected persons and frequently is the first indicator of progression to symptomatic disease(8). The clinical features of the HIV infection range from seemingly asymptomatic infection through to severe clinical illness and immunodeficiency(9). Notably, understanding the natural history of a disease can help in the clinical management as well as shed light on the pathogenesis of the disorder, which in turn may lead to new therapeutic strategies and additional research pathways(10). It is against this background that

observational and epidemiological surveys to elucidate the exact pattern of prevalence of the diverse conditions and lesions associated with HIV infection and AIDS have remained important. In the resource-poor countries the benefits of extensive interventional procedures and chemotherapeutic strategies can then be rationally balanced against unnecessary treatment complications and improvement of the quality of life of the severely immunocompromised individual(11). In the present study, it is evident that the HIV/AIDS sufferers often endure a high morbidity arising from diverse lesions that may manifest concurrently.

Periodontal disease occurring with oral candidiasis can be extremely difficult to manage where medical and dental resources are limited, as is the case in our region. Some individuals with HIV infection develop forms of periodontal disease, which are more severe than conventional periodontal disease and may not respond to conventional periodontal therapy(12). These lesions include linear gingival erythema and severe and progressive periodontal disease with severe pain, bleeding, and simultaneous loss of bone and soft tissue with minimal pocketing, and necrotising stomatitis. In general the management of early periodontal disease may require minimal facilities. However, in a region where the desired ordinary facilities are unavailable, the condition will deteriorate rapidly especially in an immunosuppressed individual. In the presence of candidal infection the scenario becomes even more complicated since effective antifungal treatment has become increasingly expensive such that few individuals can afford even a short course of treatment. The quality of life among those afflicted can, therefore, only be described as dismal.

In our region, the occurrence of OKS is probably pathognomonic of the fullblown state of AIDS. Since there is no curative therapy for OKS, management is directed at control and palliation; in which case treatment options should be selected based upon location, degree and site of involvement(13). All the cases encountered in our survey had the florid type of OKS. In this state, systemic dissemination of the lesions must be considered if any useful treatment modality may be contemplated. Unfortunately in our resource-poor regions, the means for the appropriate evaluation of the extent of the disease are generally limited. Thus, the treatment considerations which include selection of local therapy for local involvement, regional therapy for regional involvement and systemic therapy for systemic involvement(13) may be hardly applicable. In the present series, albeit small, the rate of occurrence of OKS at 13% is considerable in terms of the comprehensive general investigation of the patients for effective management. Furthermore, the unavailability of even the most basic facilities for any form of treatment has made the situation increasingly daunting among clinicians encountering this neoplasm.

Other lesions that may be amenable to effective medical treatment include the herpes simplex and herpes zoster infections. It is interesting that in this survey their

rate of occurrence was somewhat lower than would have been anticipated. Quite unhappily the medical management of these infections remains prohibitively expensive for most afflicted individuals. However, treatment available in our setup included: anti-fungal agents such as nystatin and ketoconazole for candidiasis, corticosteroid preparations such as triamcinolone for recurrent aphthous ulcers; and where possible excisional biopsy was performed for small lesions of OKS. The management of HIV-periodontitis/gingivitis included the administration of antibiotics in conjunction with the enhancement of meticulous oral hygiene.

It may be observed that with the progression of the disease, the occurrence of oral manifestations was high and suggestive of poor prognosis as far as HIV infection was concerned. However, no direct link could be found between some systematic diseases such as tuberculosis or gastroenteritis with any oral lesion.

Besides documenting oral lesions in the HIV disease and AIDS, the present survey has also yielded socio-demographic information consistent with that already recorded in diverse regions of the world. The peak age group at which this dreadful disease occurs remains particularly important since it should be the main target for preventive measures and interceptive treatment modalities. The fact that the peak occurrence of the disease is, undoubtedly, within the age bracket of 30 to 45 years is a major threat not only to the regional economies but also to the entire world. From the present data it appears that male persons in paid employment may be more susceptible to exposure to the AIDS virus. This probably implies that the financial well being of the male individuals may induce them into the high risk indulgences that have been closely associated with the occurrence of the HIV infection. On the other hand, it is apparent that the unemployed female individuals may be particularly susceptible to exposure to the HIV infection since they may be driven into having multiple sex partners as a means of financial gains. No wonder then that the levels of HIV infection among the rural populations of most of Africa are likely to continue to rise in the wake of the current widespread economic constraints. Sadly, under such conditions that make basic survival ever so difficult, even the notably viable preventive educational measures may be hard to be accepted and assimilated at the grassroots in rural Africa. Undoubtedly, this poses immediate major problems since the means by

which the economies of the East and Southern Africa region can improve as rapidly as desired remains elusive. Notwithstanding our persistent difficulties, all the national HIV/AIDS prevention programmes must be enhanced and sustained more than ever before.

While no major conclusions may accrue from the present data, serious socio-economic implications of the occurrence of diverse clinical conditions, that are difficult to manage in a single hospital has to be a subject of particular concern for all health planners and managers.

#### ACKNOWLEDGEMENTS

We are most grateful to the Provincial Medical Officer, Coast Province; and the Coast Province General Hospital Medical Officer-in-charge for their permission to perform this study. In addition we thank all the nurses in all the medical wards for their assistance and co-operation during data collection. Finally we are greatly indebted to Ms Shamim Butt and Ms Mahjabeen Butt for preparing the manuscript.

#### REFERENCES

1. Greenspan D. and Greenspan J.S. HIV - related oral disease. *Lancet* 1996; **348**: 729-733.
2. Scully C. The HIV global pandemic: the development and emerging implications *Oral Dis.* 1997; **3** (suppl 1): S1-S6.
3. Greenspan J.S. Sentinels and signposts: the epidemiology and significance of the oral manifestations of HIV disease. *Oral Dis.* 1997; **3** (suppl 1): S13-S17.
4. Schmidt-Westhausen A., Griinewald Th, Reichart P.A. and Pohle H.D. Oral manifestations in 70 German HIV-infected women. *Oral Diseases* 1997; **3** (suppl 1): S28-S30.
5. Wanzala P., Manji F. and Pindborg J.J. *et al.* Low prevalence of oral mucosal lesions in HIV-1 seropositive African women. *J. Oral Pathol. Med.* 1989; **18**: 416-418.
6. Guthua S.W., Mwaniki D.L. and Chindia M.L. Orofacial lesions as indicators of HIV/AIDS among dental patients in Kenya. *East Afr. Med. J.* 1995; **72**: 135-138.
7. The status and Trends of Global HIV/AIDS Pandemic. Official Satellite Symposium: Final Report, July 5-6, 1996, 1-31
8. Zakrzewska J.M., Robinson P. and Williams I.G. Severe oral ulceration in patients with HIV infection - a case series. *Oral Dis.* 1997; **3** (suppl 1):S194-S196.
9. Porter S. and Scully C. HIV: the surgeon's perspective - Part 2. Diagnosis and management of non-malignant oral manifestations. *Brit. J. Oral Maxillofac. Surg.* 1994; **32**: 231-240.
10. Volberding P.A. Age as a predictor of progression in HIV infection. *Lancet.* 1996; **347**:1569-1570.
11. Hodgson T.A. HIV-associated oral lesions: prevalence in Zambia. *Oral Diseases.* 1997; **3** (suppl 1):S46-S50.
12. Winkler J.R., Herrera C., Westenhouse J. *et al.* Periodontal disease in HIV-infected and uninfected homosexual and bisexual men. *AIDS* 1992; **6**: 1041- 1043.
13. Epstein J.B. Management of oral Kaposi's sarcoma and a proposal for clinical staging. *Oral Dis.* 1997; **3** (suppl 1): S124-S128.