

Tapping for pneumoperitoneum in neonates and infants

Ibrahim A. Ibrahim and Ahmed E. Ahmed

Purpose The aim of this study was to shed some light on the presence of pneumoperitoneum in neonates and infants and to present and evaluate our method for its treatment.

Materials and methods This study included 33 patients diagnosed with pneumoperitoneum during 2004–2011, of whom 19 were girls and 14 were boys, and their ages ranged from 1 week to 5 months; 21 patients were neonates and seven of them were premature; two were aged less than 32 weeks and had mild pneumoperitoneum, which could be treated conservatively and five were aged between 32 and 34 weeks. Tapping was performed for all patients. Tapping can help in selection of patients with necrotizing enterocolitis needing exploration when the aspirate is bilious or feculent. Tapping could be performed as a temporary measure before exploration to decrease respiratory distress and the occurrence of abdominal compartment syndrome and also as a routine procedure in patients with pneumoperitoneum. Tapping is an easy procedure and can be performed with the patient in bed or in the incubator. Pneumoperitoneum is not an absolute indication for surgical exploration and a small subset of patients should be managed by laparotomy. Each patient with pneumoperitoneum should be assessed and categorized for tapping, placement of a tube drain, or surgical exploration. Pneumoperitoneum occurs in neonates more frequently than in infants, and most cases are idiopathic.

Results A total of 29 patients were treated by tapping alone (in nine patients, tapping was performed once; in 13, it was performed twice, and in the other seven,

it was performed three to four times). Rapid improvement in the general condition and respiratory distress occurred in most patients. Six patients (five neonates and one infant) were explored because of: (a) aspiration of a bile-stained or feculent fluid in two patients and (b) failure of conservative treatment in four patients.

Conclusion Pneumoperitoneum occurs in neonates more than infants and most cases are idiopathic. Each case of pneumoperitoneum should be assessed and categorized for tapping, placement of a tube drain or surgical exploration. Pneumoperitoneum is not an absolute indication for surgical exploration and small subset of patients should be managed by laparotomy. Tapping is an easy job and can be done with the patient in bed or in the incubator. Tapping could be performed as a routine in cases of pneumoperitoneum. Tapping could be done as a temporary measure before exploration to decrease respiratory distress and abdominal compartment syndrome. *Ann Pediatr Surg* 9:47–53

© 2013 Annals of Pediatric Surgery.

Annals of Pediatric Surgery 2013, 9:47–53

Keywords: infants, neonates, pneumoperitoneum, tapping

Pediatric Surgery Unit, General Surgery, Department, Faculty of Medicine, Assiut University, Assiut, Egypt

Correspondence to Ibrahim A. Ibrahim, MD, Pediatric Surgery Unit, General Surgery, Department, Faculty of Medicine, Assiut University, Assiut, Egypt
Tel: +20 882 290 940/+20 105 801 291; fax: +20 882 334 541;
e-mail: dr.ibrahimali@yahoo.com

Received 24 September 2011 accepted 4 January 2013

Introduction

The most common cause of pneumoperitoneum is perforation of an abdominal viscus that can occur at any age [1,2].

In neonates, the most likely cause is gastric perforation, secondary to necrotizing enterocolitis (NEC), or an intestinal obstruction. In addition, there may be iatrogenic causes, such as perforation from a nasogastric tube [3,4].

In older infants and children, the causes are many and may include a blunt trauma with rupture of a hollow viscus, penetrating trauma, perforation of the gastrointestinal (GI) tract (from a gastric or duodenal ulcer, stress ulcer, ulcerative colitis with toxic megacolon, Crohn's disease, and bowel obstruction), steroid treatment, infection in the peritoneum with gas forming organisms, or rupture of an abscess, or it may be because of thoracic problems such as pneumomediastinum [3].

Presence of a pneumoperitoneum does not, however, always imply a perforation, because a number of other (mostly nonsurgical) conditions are associated with it; likewise, not every bowel perforation results in a pneumoperitoneum [5,6].

The clinical features depend on the cause of the pneumoperitoneum.

A pneumoperitoneum that has a benign cause and is unaccompanied by peritonitis is usually asymptomatic. In such cases, the pneumoperitoneum may be an incidental finding, although occasionally, vague abdominal symptoms may occur. The symptoms from a perforated hollow abdominal viscus depend on the development of peritonitis. Peritonitis may be diffused or localized, and its severity depends on the type of GI contents released into the peritoneal cavity [3].

Pneumoperitoneum associated with peritonitis requires urgent surgery, and in other cases, it may be an incidental finding for which only observation is required [7].

Necrotizing enterocolitis

NEC represents a spectrum of diseases with variable causes and manifestations. The clinical findings are nonspecific and include lethargy, temperature instability, bradycardia, and those specifically related to the GI tract, which include abdominal distension, bloody stool, high

gastric residuals after feeding, vomiting, and diarrhea. Abdominal palpation may elicit palpable bowel loops, a mass, or abdominal wall crepitus [8].

The diagnosis is usually suspected clinically but often requires the aid of diagnostic imaging modalities. Radiographic signs of NEC include, dilated bowel loops, paucity of gas, a 'fixed loop' (unaltered gas-filled loop of bowel), pneumatosis intestinalis, portal venous gas, and pneumoperitoneum. The pathognomonic finding on plain films is pneumatosis intestinalis. More recently, ultrasonography (US) has proven to be useful as it may detect signs and complications of NEC before they are evident on radiographs. Diagnosis is ultimately made in 5–10% of children with a very low birth weight [9].

Treatment consists primarily of supportive care, including providing bowel rest by stopping enteral feeds, gastric decompression with intermittent suction, fluid repletion to correct electrolyte abnormalities and third space losses, support for blood pressure, parenteral nutrition, and prompt antibiotic therapy. Monitoring is clinical, although serial supine and left lateral decubitus abdominal roentgenograms should be performed every 6 h [10].

The principle goal of surgical intervention is to remove the gangrenous bowel. The most widely accepted indication for surgery is pneumoperitoneum [11].

Other relative indications for operative intervention are erythema in the abdominal wall, gas in the portal vein, and positive paracentesis. Contraindications to surgical intervention include patients with stage I or stage II disease for whom nonoperative medical therapy is the treatment of choice. In addition, surgical intervention should be deferred in patients with more severe disease whose condition responds to initial medical management [12].

Patients and methods

The study protocol was approved by the ethics committee of our institution and informed consent was obtained from the parents; the technique, expected results, and possibilities of surgical exploration were explained to them.

This study included 33 patients diagnosed with pneumoperitoneum during 2004–2010, of whom 19 were girls and 14 were boys, and their ages ranged from 1 week to 5 months; 21 patients were neonates and seven of them were premature; two were aged less than 32 weeks and five were aged between 32 and 34 weeks. The mean weight was 2455 g for the mature neonates and 1630 g for the premature ones. Eleven patients were older than 1 month, one patient was aged 40 days, one was aged 50 days, one was aged 5 months, and the rest were younger than 5 months.

A total of 28 patients were presented because of severe abdominal distension, respiratory distress, scrotal swelling, and a history of passing stool. There were no abdominal signs of peritonitis or intestinal ischemia. Three neonates had scrotal swelling (pneumosrotum);

one of them was premature and the other two had surgical emphysema of the abdominal wall.

Five neonates were diagnosed as having NEC with pneumoperitoneum; two of them were premature and the other three were full-term. The diagnosis was evident clinically. There was abdominal distension and bloody stool in all five patients; two had leukopenia and one had thrombocytopenia.

Pneumoperitoneum was detected using plain abdominal radiography and abdominal US for all patients.

All patients were subjected to routine investigations: complete blood test, coagulation profile, renal function tests, and determination of blood sugar and serum electrolytes.

Tapping technique

Tapping is performed under complete aseptic conditions. The abdominal circumference is measured and the abdomen is sterilized with povidone-iodine and alcohol. The patient is put in the Fowler position (as near as possible to the erect position).

Tapping is performed using a No. 20, 22, or 24-G cannula to the right, just below the xiphisternum. The cannula is introduced gently into the abdomen by an angle of 45° until release occurs, the trochar is extracted and the cannula is progressed into the abdomen. A syringe is attached to the cannula and aspiration is performed by applying gentle pressure to the abdomen; this is repeated until the abdomen becomes flat or the aspiration becomes negative. The cannula and the syringe are extracted. The site of aspiration is resterilized and a small piece of gauze is put over it; the patient is returned to the supine position, the abdominal circumference is remeasured and plain radiographs of the abdomen are taken. The patient is kept on intravenous fluids for 3–5 days and on a systemic combination of antibiotics for 7 days.

Follow-up

- (1) Clinical assessment: All patients were monitored for:
 - (i) Pulse, blood pressure, and temperature.
 - (ii) Abdominal circumference (measured every 6 h).
 - (iii) Abdominal signs of peritonitis.
 - (iv) Stool passage.
- (2) Plain erect abdominal radiographs:
 - (i) Were taken immediately after tapping and thereafter, according to the patient's progress.
- (3) Abdominal US (daily):
 - (i) The patient is kept on intravenous fluids for 3–5 days, then started gradual oral feeding.

Repetition of tapping

As long as the clinical and investigatory conditions of the patient were stable, tapping was not repeated. Tapping was repeated when there was reaccumulation of air (which increased the abdominal circumference to the size before tapping).

- (1) Criteria for continuing conservative treatment:

- (i) Soft, lax abdomen with stable or decreasing abdominal circumference.
 - (ii) Passing stool.
 - (iii) No constitutional signs of peritonitis or septicemia.
 - (iv) Tolerance to oral feeding without vomiting or reaccumulation of air.
- (2) Criteria for surgical exploration:
- (i) Rapid reaccumulation of air needing tapping more than twice per day.
 - (ii) Appearance of signs of peritonitis or septicemia.
 - (iii) Absolute constipation.
 - (iv) Intraperitoneal fluid increasing in amount and turbid on sonography or on tapping.
- (3) Aspiration of feculent or bile-stained fluid:
- (i) Reaccumulation of air or appearance of signs of peritonitis when the patient starts oral feeding.

Results

This study included 33 patients, of whom 27 were cured by tapping alone (in nine patients, tapping was performed once; in 13, it was performed twice; and in the other seven, it was performed three to four times). Patients with residual mild pneumoperitoneum, a stable general condition, normal body temperature, and a within-normal leukocyte count and without signs of peritonitis, which comprised six patients out of the nine who were subjected to tapping only once, were continued on conservative treatment only. In the other three patients, there was complete disappearance of the pneumoperitoneum. A few cubic centimeters of clear serous fluid exuded at the end of tapping in two infants, one aged 40 days and the other aged 2 months, and both were subjected to tapping only once.

Rapid improvement in the general condition and respiratory distress occurred in most patients.

Three neonates, two of whom were premature, had patent processus vaginalis presented as a tense scrotal swelling (pneumosrotum), which was compressible as the air returned back to the peritoneal cavity. One of the three neonates had spontaneous surgical emphysema of the abdominal wall, and in another neonate, surgical emphysema occurred on attempting to reduce the air in the peritoneal cavity. These three patients responded to the single tapping with complete disappearance of the pneumatocele, in one patient, the subcutaneous air was aspirated once, and they were discharged.

- (1) Six patients (five neonates and one infant) were explored because of:
- (i) Aspiration of a bile-stained or feculent fluid in two patients.
 - (ii) Failure of conservative treatment in four patients.

Operative details

After correction of the general condition, the patient was taken to the operation theater and explored by a right transverse supraumbilical incision not reaching the midline.

In one patient aged 7 days, there was a single cecal perforation of less than 1 cm in diameter that was treated by simple closure. In one female patient aged 25 days with NEC, there was a single perforation of 1.5×2 cm in the sigmoid colon. She had fecal peritonitis and a congested colon with multiple pyogenic membranes on its wall. The perforated part was exteriorized as a colostomy with a biopsy taken from the colon distal to the site of the perforation, and Hirschsprung's disease was ruled out. The colostomy was closed after 2 months.

In one neonate, there were multiple ileal perforations that were treated by resection and ileoileal anastomosis, the rest of the intestine was congested and covered by pyogenic membranes.

Two preterm neonates with NEC had multiple colonic and ileal perforations that were treated by resection and anastomosis and covering ileostomy. They died because of septicemia.

In one infant aged 5 months, the exploration revealed a single perforation of 1×1.5 cm in the transverse colon that was treated by resection and colocolic anastomosis. The rest of the intestine was healthy with a minimal amount of turbid peritoneal fluid. A biopsy from the edges of the perforations revealed necrotic edges with inflammatory cell infiltrate.

Discussion

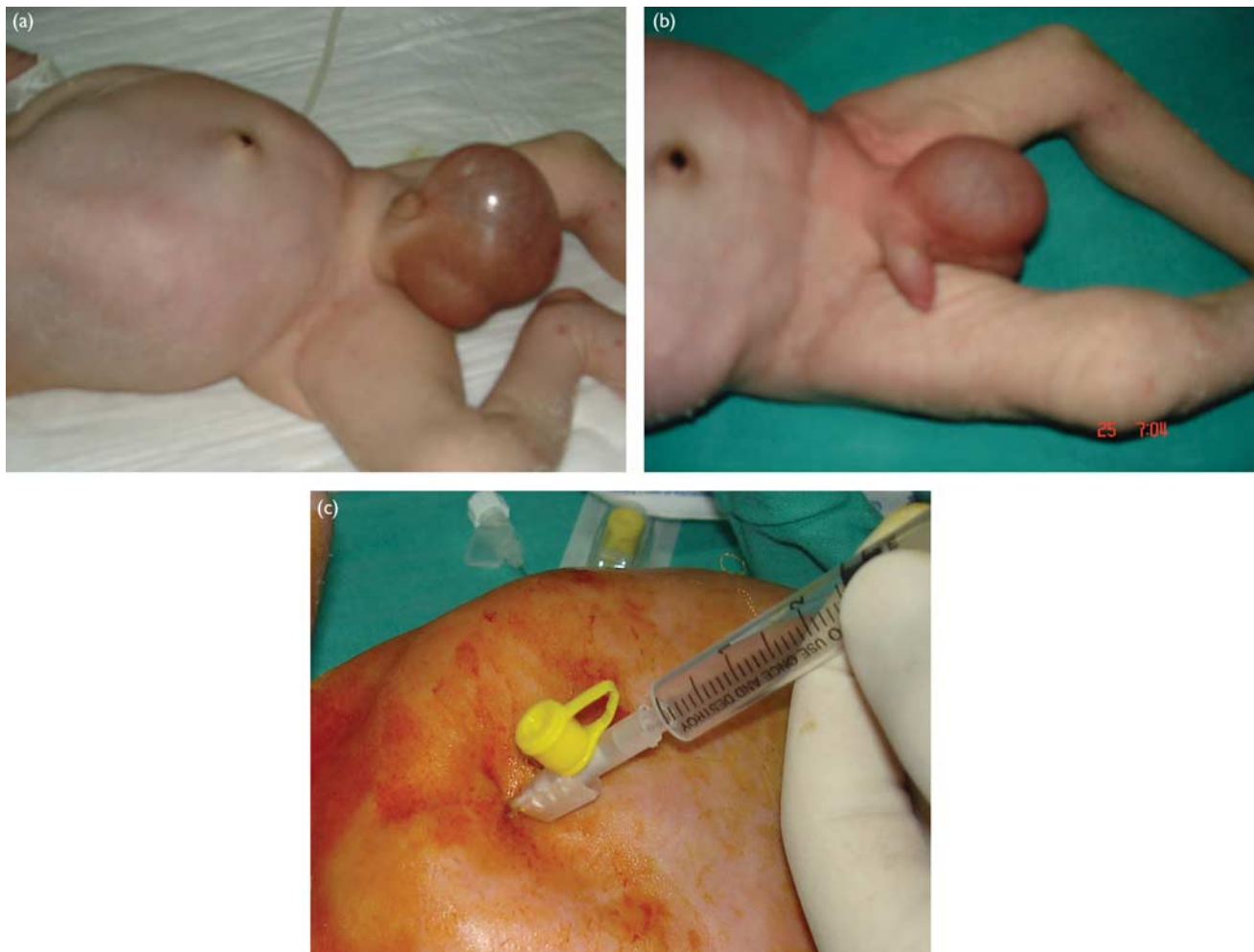
Pneumoperitoneum refers to the presence of air in the peritoneal cavity. It is considered a surgical emergency owing to its many potentially devastating causes. Abdominal radiography is sufficient to diagnose and manage the patient because it is as accurate as computed tomography, as long as the entire abdomen is imaged [3]. US is usually the first investigation performed in emergent patients. US is a noninvasive test that is widely available and is particularly valuable in children; some studies have reported its sensitivities in the diagnosis of pneumoperitoneum being higher than that of plain abdominal radiography [13]. Compared with plain radiography, US examination also has the advantage of depicting other changes such as free abdominal fluid and inflammatory masses [14]. Contrasting studies on the bowel may be helpful to confirm a perforation in the GI tract. If such studies are to be carried out, a low or iso-osmolar water-soluble contrast should be used, as hyperosmolar contrasts may cause further damage [3].

In our study, we were dependent on the clinical assessment, plain radiography of the abdomen, and abdominal US. Other investigations for diagnosis of pneumoperitoneum in our patients were not required. None of our patients were subjected to contrast-based examinations as it is risky in patients with suspected intestinal perforation.

Gas in the scrotum is present usually inside a herniated bowel, but it can be the first sign of pneumoperitoneum [15].

In three of our patients, the diagnosis was mainly clinical as they presented with a pneumosrotum that reduced

Fig. 1



(a) A patient with pneumoperitoneum, pneumoscrotum, and surgical emphysema of the abdominal wall. (b) Pneumoperitoneum reduced to the peritoneal cavity before tapping. (c) Tapping.

completely to the abdomen and reappeared by compression of the abdominal wall. Two patients had surgical emphysema of the abdominal wall, which was spontaneous in one patient and occurred during reduction of the pneumoscrotum back to the abdomen in the other. We suggest that its occurrence resulted from the rupture of the processus vaginalis, with the escape of air subcutaneously.

Detection of a pneumoperitoneum by chest radiography and computed tomography scans, without any cause or evidence of perforation of the viscus should be defined as an idiopathic nonsurgical pneumoperitoneum (NP). NP may be caused by subclinical microperforation of the hollow viscus. Subclinical microperforation permits the escape of gases from the bowel, without leakage of the bowel contents. Usually, peritonitis is absent, and the vitals are stable in majority of the patients [16].

Moreover, pneumoperitoneum may result from mechanical ventilation, pneumomediastinum, or pneumothorax [4].

Most of our patients had idiopathic pneumoperitoneum. None of the patients had associated pneumothorax or pneumomediastinum, nor were they mechanically ventilated

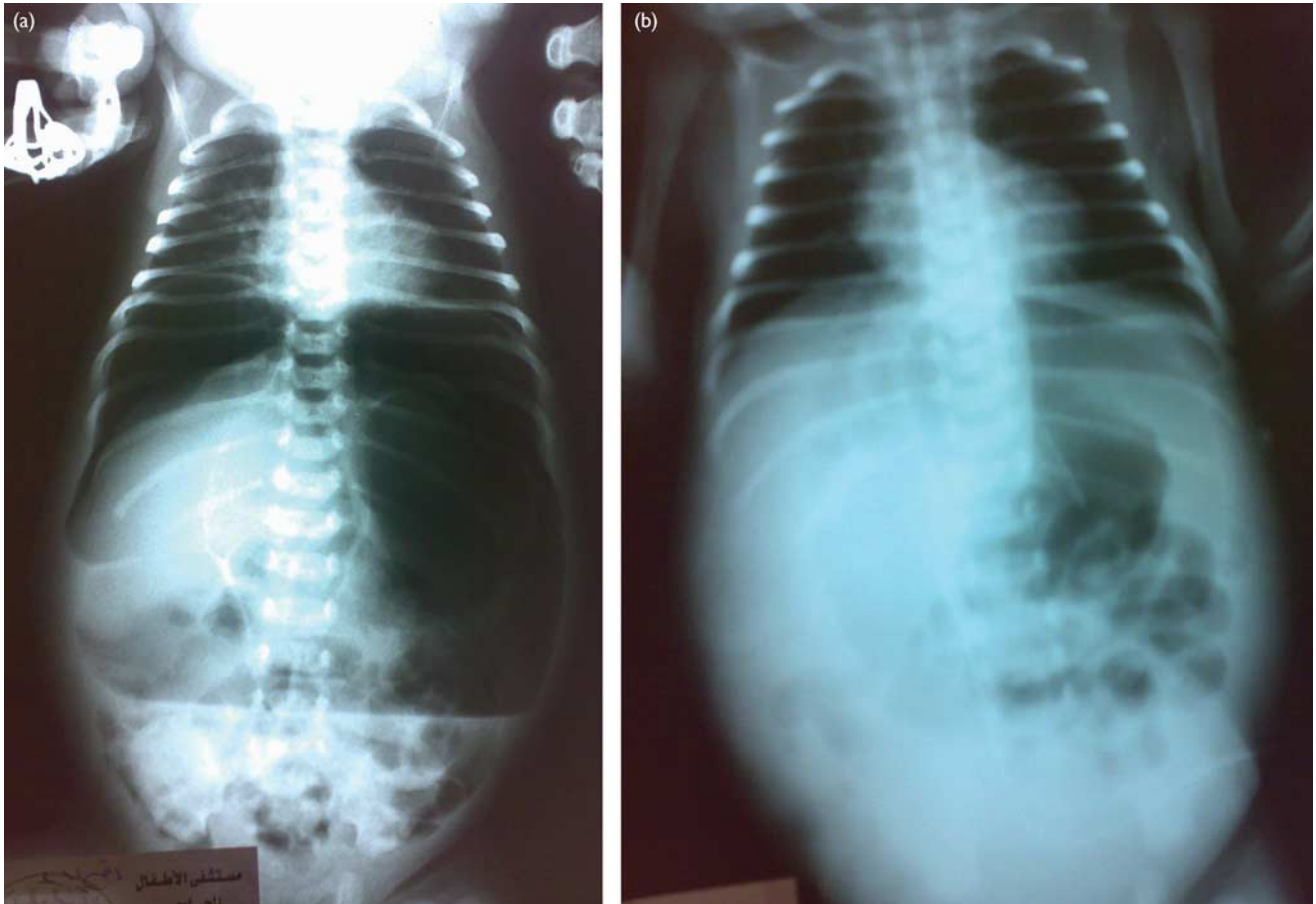
at the time of presentation; reaccumulation of air after tapping occurred in a large number of our patients. Therefore, the possibility of microperforation of the viscus is the likely reason for the pneumoperitoneum in our patients.

There is a general consensus that pneumoperitoneum without peritonitis can be treated conservatively, either by supportive treatment and follow-up or by peritoneal lavage. Only a small subset of patients with evidence of peritonitis or deterioration on conservative treatment should be managed by laparotomy [16].

In contrast, there are many reports on the negative exploration of patients with pneumoperitoneum [16,17]. Al-Salem [18] reported a newborn with pneumoperitoneum and free meconium passage without GI perforation. Karaman *et al.* [6] reported six patients with NP, four of whom were treated conservatively after performing a diagnostic peritoneal lavage and two were explored without evidence of intestinal perforation.

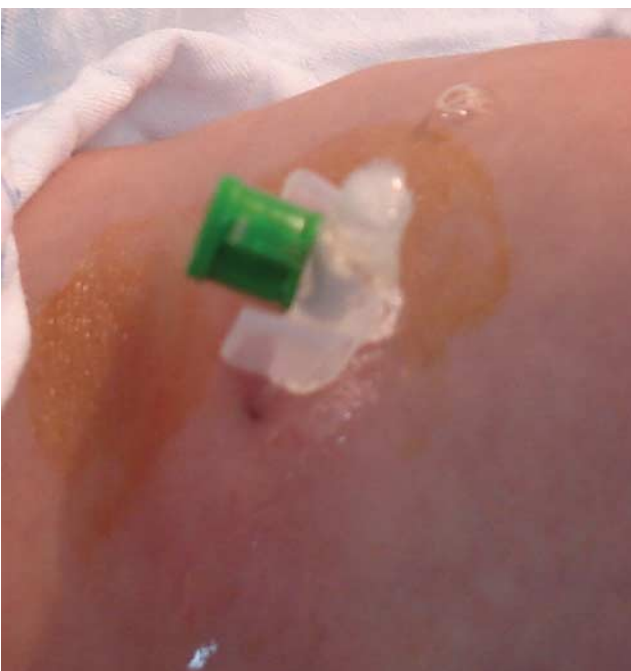Mularski *et al.* [19] reviewed 196 reported cases of NP, of which 45 underwent surgical exploration without evidence of a perforated viscus. Furthermore, Khan *et al.* [20] reported a series of 34 neonates with pneumoperitoneum; of the 32

Fig. 2



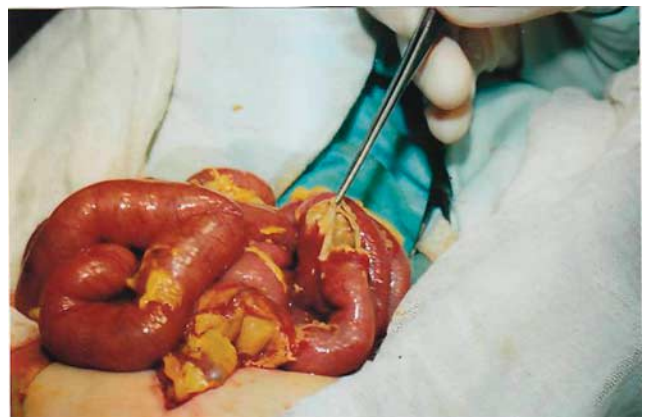(a) A plain radiograph showing massive pneumoperitoneum. (b) Radiograph after tapping.

Fig. 3



Air and clear serous fluid coming out spontaneously through the cannula.

Fig. 4

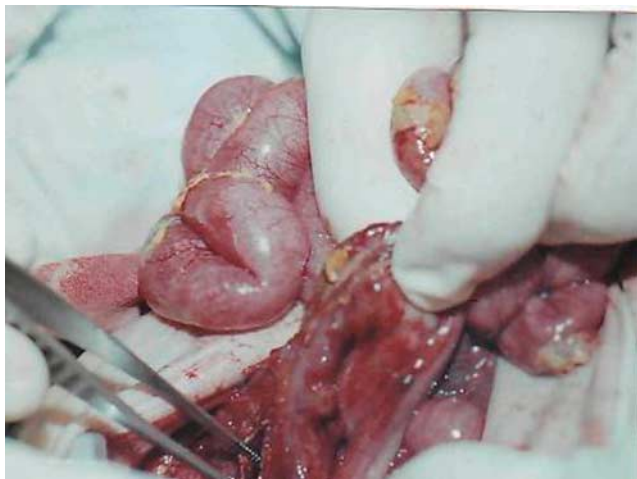

Multiple ileal perforations.

patients with features of peritonitis, 28 were managed with flank drains alone, whereas four underwent laparotomy and two were managed conservatively.

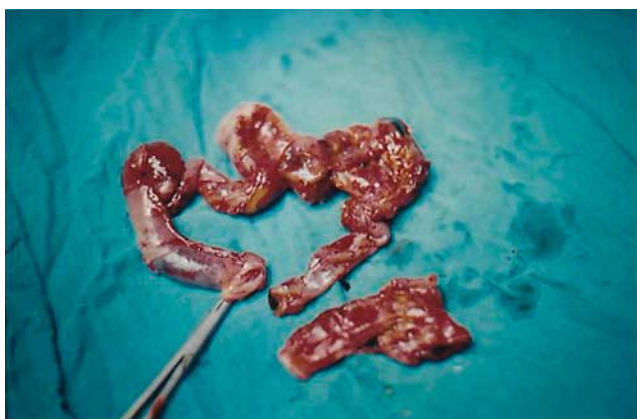We suggest tapping in patients with pneumoperitoneum without peritonitis as it results in immediate relief from abdominal distension, improves respiration, prevents abdominal compartment syndrome, and also avoids the

Fig. 5



The perforated sigmoid.

Fig. 6



The resected ileal loop.

possibility of negative exploration. Most of our patients improved on tapping without exploration, and we did not have any negative exploration cases.

Tapping is performed below the xiphisternum, slightly to the right. This area is relatively safe as it is away from the intestine, is spaced from the liver by the intraperitoneal air, and is to the right of the falciform ligament, and this was proven in the explored patients in whom there were no complications as a result of tapping.

In patients with peritonitis, it is better to perform exploratory laparotomy than conservative treatment [16]. Patients who presented with peritonitis associated with pneumoperitoneum were excluded from our study and subjected to laparotomy. However, even in these patients, tapping could be performed as a temporary measure before exploration to improve the general condition. Tapping may reveal clear fluid coming out along with air, and this is insignificant as long the aspirate is a clear serous fluid. If the aspirate is bilious or feculent,

exploration is indicated; this occurred in two of our explored patients.

NEC is the most common GI medical/surgical emergency in neonates. Nonoperative support is needed in 70% of patients with NEC and surgical intervention in the remaining 30% [21].

NEC typically occurs during the second to third week of life of an infant who is premature and has been formula-fed. Although various clinical and radiographical signs and symptoms are used to perform the diagnosis, the classic clinical triad consists of abdominal distension, bloody stools, and pneumatosis intestinalis [12].

Occasionally, the signs and symptoms include, temperature instability and lethargy; the other principle indication for operative intervention is a perforated or necrotic intestine. Infants with necrotic intestines are identified on the basis of various clinical, laboratory, and radiological findings. The most compelling predictor of intestinal necrosis indicating a need for operative intervention is pneumoperitoneum.

Historically, pneumoperitoneum has been considered as an absolute indication for laparotomy [21,22]. Other relative indications for operative intervention are erythema in the abdominal wall, gas in the portal vein, and positive paracentesis [15].

Andiran *et al.* [22] reported a case of a 3-day-old male newborn with NEC in whom a pneumoperitoneum subsequently developed without any cause and was detected by laparotomy. They suggest nonsurgical management of NEC associated with pneumoperitoneum in selected patients.

Upadhyaya *et al.* [21] after a study on 58 patients with NEC associated with pneumoperitoneum, emphasized that pneumoperitoneum is not an absolute indication for exploratory laparotomy in patients with NEC.

Five of our patients were diagnosed as having NEC with pneumoperitoneum. Tapping was performed for all the patients. Two patients improved on tapping and medical treatment. Three patients were explored, two of whom were explored after the first tapping because of the aspiration of a bilious fluid; their exploration revealed multiple colonic and ileal perforations that were treated by resection and anastomosis and proximal ileostomy, they died postoperatively because of septicemia. One patient was explored after failure of conservative treatment with rapid reaccumulation of the pneumoperitoneum. Exploration revealed a single perforation of the sigmoid colon exteriorized as a colostomy. Tapping can help in selection of patients with NEC needing exploration when the aspirate is bilious or feculent. Nonsurgical treatment of NEC with pneumoperitoneum is feasible in selected patients.

Contraindications to surgical intervention include patients with stage I or stage II disease for whom nonoperative medical therapy is the treatment of choice. In addition, surgical intervention should be deferred in patients with more severe disease, whose condition responds to initial medical management. Critically ill newborns with a relative contraindication to formal

operative exploration may be treated with the placement of a peritoneal drain [5]. A peritoneal drain may provide temporary stabilization and recovery, but most of the critically ill newborns require subsequent laparotomy [20].

Based on our study, pneumoperitoneum could be as follows:

Simple pneumoperitoneum without signs of peritonitis or massive distension, and this type can be treated conservatively.

Massive pneumoperitoneum with distension and respiratory distress, without signs of peritonitis, and this type can be treated by tapping.

Pneumoperitoneum with peritonitis, and this type needs surgical exploration or placement of a peritoneal drain (Figs. 1–6).

Conclusion and recommendations

- (1) Pneumoperitoneum occurs in neonates more frequently than in infants, and most cases are idiopathic.
- (2) Each patient with pneumoperitoneum should be assessed and categorized for tapping, placement of a tube drain, or surgical exploration.
- (3) Pneumoperitoneum is not an absolute indication for surgical exploration, and a small subset of patients should be managed by laparotomy.
- (4) Tapping is an easy procedure and can be performed with the patient in bed or in the incubator.
- (5) Tapping could be performed as a temporary measure before exploration to reduce respiratory distress and the occurrence of abdominal compartment syndrome.
- (6) Tapping can help in selection of patients with NEC needing exploration when the aspirate is bilious or feculent.
- (7) Mild cases of pneumoperitoneum can be treated conservatively.

Acknowledgements

Conflicts of interest

There are no conflicts of interest.

References

- 1 Higham J, Kang JY, Majeed A. Recent trends in admissions and mortality due to peptic ulcer in England: increasing frequency of haemorrhage among older subjects. *Gut* 2002; **50**:460–464.
- 2 De Laet MH, Dassonville M, Johansson A, Lermieux C, Seghers V, Van den Eijnden S, et al. Small-bowel perforation in very low birth weight neonates treated with high-dose dexamethasone. *Eur J Pediatr Surg* 2000; **10**:323–327.
- 3 West J, Silberberg P, Babyn P. Pneumoperitoneum: radiology teaching files>Case 5463105. 2006. Available at: [http://www. MyPACS.net](http://www.MyPACS.net).
- 4 Khan YA, Akhtar J. Pneumoperitoneum: a rare presentation of gastric perforation in a neonate. *APSP J Case Rep* 2010; **1**:15 [Epub 1 December 2010].
- 5 Mularski RA, Ciccolo ML, Rappaport WD. Nonsurgical causes of pneumoperitoneum. *West J Med* 1999; **170**:41–46.
- 6 Karaman A, Demirbilek S, Akin M, Gürnlüoğlu K, Irşi C. Does pneumoperitoneum always require laparotomy? Report of six cases and review of the literature. *Pediatr Surg Int* 2005; **21**:819–824.
- 7 Khan AN. Pneumoperitoneum. 2011. Available at: [http://eMedicine. Medscape.com](http://eMedicine.Medscape.com) [Accessed 15 August 2011].
- 8 Chandler JC, Hebra A. Necrotizing enterocolitis in infants with very low birth weight. *Semin Pediatr Surg* 2000; **9**:63–72.
- 9 Hunter CJ, Upperman JS, Ford HR, Camerini V. Understanding the susceptibility of the premature infant to necrotizing enterocolitis (NEC). *Pediatr Res* 2008; **63**:117–123.
- 10 Leigh L, Stoll BJ, Rahman M, McGowan J Jr. *Pseudomonas aeruginosa* infection in very low birth weight infants: a case–control study. *Pediatr Infect Dis J* 1995; **14**:367–371.
- 11 Fasoli L, Turi RA, Spitz L, Kiely EM, Drake D, Pierro A. Necrotizing enterocolitis: extent of disease and surgical treatment. *J Pediatr Surg* 1999; **34**:1096–1099.
- 12 Chen LE, Minkes RK, Bloss RB. Necrotizing enterocolitis, surgical treatment. 2011. Available at: [http://eMedicine. Medscape.com](http://eMedicine.Medscape.com).
- 13 Chen SC, Yen ZS, Wang HP, Lin FY, Hsu CY, Chen WJ. Ultrasonography is superior to plain radiography in the diagnosis of pneumoperitoneum. *Br J Surg* 2002; **89**:351–354.
- 14 Ottinger D, Swanson JR. Diagnosing intestinal perforation: a new approach. *Am J Perinatol* 2008; **25**:291–294.
- 15 Koh CC, Sheu JC. Intestinal atresia presenting as bilateral scrotal pneumatocele: a case report. *J Pediatr Surg* 2002; **37**:E2.
- 16 Tiwary SK, Agarwal A, Kumar S, Khanna R, Khanna AK. Idiopathic massive pneumoperitoneum. *Internet J Surg* 2006; **8**:2.
- 17 Köklü E, Akçakuş M, Turan C, Altunay L, Canpolat M. Benign pneumoperitoneum in a newborn: a case report. *Erciyes Med J* 2007; **29**:245–247.
- 18 Al-Salem AH. Pneumoperitoneum and free meconium without gastrointestinal perforation in a neonate. *Saudi Med J* 2000; **21**:680–682.
- 19 Mularski RA, Sippel JM, Osborne ML. Pneumoperitoneum: a review of nonsurgical causes. *Crit Care Med* 2000; **28**:2638–2644.
- 20 Khan R, Mahajan J, Rao KL. Spontaneous intestinal perforation in neonates: is surgery always indicated. *Afr J Paediatr Surg*. **8**:2011. pp. 249–251.
- 21 Upadhyaya VD, Gangopadhyay AN, Pandey A, Upadhyaya A, Mohan TV, Gopal SC, Gupta DK. Is pneumoperitoneum an absolute indication for surgery in necrotizing enterocolitis? *World J Pediatr* 2008; **4**:41–44.
- 22 Andiran F, Dayi S, Dilmen U. Pneumoperitoneum: an absolute indication for surgery in infants with necrotizing enterocolitis?: Report of a case. *Surg Today* 2001; **31**:250–252.