

Full Length Research Paper

A comparative study of lyophilized bovine pericardium and tunica parietalis vaginalis for repair of large abdominal wall defects in a rabbit model

Taddese Ayele^{1,2}, Zuki, A. B. Z.^{1*}, Noorjahan, B. M. A.³ and Noordin, M. M.¹

¹Faculty of Veterinary Medicine, University Putra Malaysia, 43400 UPM, Serdang, Selangor Darul Ehsan, Malaysia.

²Faculty of Veterinary Medicine, University of Gondar, P. O. Box 196, Gondar, Ethiopia.

³Faculty of Biotechnology and Bimolecular Sciences, University Putra Malaysia, 43400 UPM, Serdang, Selangor Darul Ehsan, Malaysia.

Accepted 20 June, 2011

The aim of this study is to investigate the effectiveness of lyophilized bovine pericardium and tunica vaginalis in repairing large abdominal wall defect in a rabbit model. Full thickness (all the layers of muscles except the skin) abdominal wall defects (3 x 4 cm) were created in 18 anaesthetized male clinically healthy New Zealand white rabbits and randomly divided into two equal group (n= 9 each). The defects of the first group were repaired with bovine pericardium, whereas the second group was with bovine tunica vaginalis parietalis. Three animals were sacrificed at 7th, 14th and 30th days of post-implantation from each group and the explanted specimens were subjected to macroscopic and microscopic examinations. The explanted grafts were replaced by newly formed collagen fibres and neo-vascularisation without any infection as well as formation of seroma. The cellular reaction was almost similar in each group. Therefore, these scaffolds can provide a structural replacement for severe and large abdominal wall defects.

Key words: Lyophilized, bovine pericardium, bovine tunica vaginalis parietalis, abdominal wall defect, rabbit.

INTRODUCTION

Surgical repair of large abdominal wall defects remain a significant problem for patients and surgeons due to insufficient autogenous tissue for adequate abdominal wall closure and hence, it is inevitable to avoid the use of biomaterials (Lai et al., 2003; Gangwar et al., 2006). The use of biomaterial for the repair of abdominal wall defects is gaining increasing recognition to achieve a tension-free repair and has resulted in a significant reduction in post-operative pain, length of recovery period and the number of recurrence (Amid, 1997). The ideal biomaterials for abdominal wall repair should possess adequate strength, no hypersensitivity reactions and biocompatibility to facilitate tissue ingrowths, which may help long-term maintenance of mechanical strength (Lai et al., 2003).
In repair of abdominal wall defects, biological

biomaterials has an edge over synthetic prosthetic materials like minimal adhesion formation, better framework for fibroblast proliferation and neovascularization and moreover, multidirectional fibrous structure helps in better suture retention and are completely absorbed in body and replaced by host tissue (Decurtins and Buchman, 1982; Singh et al., 2008). However, biological biomaterials in their naturally occurring form tend to deteriorate over time and hence, to achieve safe long-term storage, minimize the immunogenicity of the graft, maintain graft mechanical integrity and natural compliance, it is generally necessary to alter the physiochemical state of the biomaterials (Park and Bronzino, 2003; She, 2006).

Lyophilization is a dual stage process that consists of rapidly cooling the liquid material to its solid form and subsequent drying (or removing) the solidified solvent (Franks, 1998), which can be solely used for preservation of bioprotheses (James et al., 1991) or in combination with gamma irradiation prior to surgical application (Cornu et al., 2000), with no significant effects on the

*Corresponding author. E-mail: zuki@vet.upm.edu.my. Tel: +603 89468301. Fax: 603 8946 8333.

biomechanical properties of bovine pericardium (Hafeez et al., 2005). Lyophilized bovine pericardium and bovine tunica vaginalis biological biomaterials are used in this study. Despite their availability and potential, far too little attention has been paid to their use in reconstructive surgery of abdominal wall defects. In addition, there has been little discussion for their clinical success especially for tunica vaginalis parietalis. Therefore, the aim of this study is to investigate the effectiveness of lyophilized bovine pericardium and tunica vaginalis parietalis in repairing of abdominal wall defect in rabbit model.

MATERIALS AND METHODS

Preparation of lyophilized bovine pericardium and tunica vaginalis

Fresh bovine pericardium and tunica vaginalis parietalis sacs were collected from abattoir. Immediately, the adherent fat and fascia were removed and washed thoroughly under running tap water, disinfected in 0.05% sodium hypochlorite and shaken three times in serial changes of sterile normal saline for 20 min each. The sacs were then spread on freeze-drier steel dishes and stored in a deep freezer overnight at -80°C. The steel dishes containing the grafts were transferred into Christ Loc-1 freeze-drier (Braun Diessel Biotech, Germany) adjusted at -40°C for 24 h under vacuum pressure of 0.12 mbar. The freeze-drier condenser temperature and shelf temperature during freeze-drying process were -40 and -30°C, respectively. The lyophilized graft were cut into identical pieces of 3 × 4 cm, sealed in airtight double-layered polyethylene bags and sterilized by 25 kGy gamma rays (Cobalt 60, JS8900, IR-174) and stored at room temperature until implantation.

Experimental animals

A total of eighteen male clinically healthy New Zealand white rabbit weighing 3 to 3.5 kg were used in the study. All the experiments were performed in compliance with the principles and guide to ethical use of laboratory animals approved by University Putra Malaysia, Faculty of Veterinary Medicine's Animal Care and Use Committee.

Surgical technique

The animals were randomly divided into two equal groups (I and II) of nine animals each. The rabbit were withheld food and water for 6 h prior to the operation and anesthetized by intramuscular injection of a mixture of 35 mg/kg ketamine hydrochloride (TROY, Australia) and 5 mg/kg of xylazine hydrochloride (TROY, Australia). The anesthesia was maintained by 1% /minute isoflurane throughout the entire procedure. The animals were secured in dorsal recumbency and the abdominal wall was shaved and washed using 4% chlorhexidine (Pharmaniaga, Malaysia), scrubbed with povidone-iodine solution and draped with the aperture of the fenestrated drape at the intended operation site. A long 6 cm mid-ventral skin incision was made and the 3 × 4 cm whole layer of abdominal wall defects which include the whole muscle layers at the mid ventral abdominal region was created. In group I, the defects were repaired by bovine pericardium, whereas in group II, the defects were repaired by bovine tunica vaginalis parietalis scaffolds. The implants were placed in a direct contact with visceral organs, subcutaneous tissue and sutured to the edges of the defect with a

simple continuous suture pattern using 3-0 silk (DemeTECH, USA) suture material, except at the corners where interrupted suture pattern were applied (Figure 1). The skin were apposed over the operated area in all operated rabbits and sutured with intradermal continuous suture pattern using 3-0 silk (DemeTECH, USA) suture material to avoid self-mutilation of the suture. Post-operatively, the operated rabbits were kept in individual cages after they recovered from the general anaesthesia. Analgesia, tramadol hydrochloride at a rate of 4 mg/kg (UNICHEM, India) was given once a day for three consecutive days intramuscularly and antibiotics, streptopenicillin at a rate of 100 mg/kg body weight were administered intramuscularly for 5 consecutive days in all animals. Postoperative follow up were carried out daily up to the end of the experiment and the rabbits were monitored through a continuous and close observation for the detection of any post-surgical clinical complication, general health problem and abnormality in food and water intake. Three rabbits from each group were sacrificed at 7th, 14th and 30th days of post-implantation by using an intra-cardial injection of sodium pentobarbital (CEVA, France) at a rate of 100 mg/kg.

Macroscopic analysis

Clinically all the animals were observed for general health, behaviour and alertness throughout the study. Food and water intake were also observed for one hour each time in the morning and in the evening. Macroscopically, the abdominal wall defect areas were examined carefully for detection of postoperative healing complications and to estimate the degree of adhesion formation between the implant and the abdominal viscera. The skin covering the abdominal wall was gently detached and cut off. The abdominal wall including the operated area was cut, lifted gently and examined carefully on the inner surface for the development of new peritoneum, vasculature, connective tissue, muscle tissue and for the detection of healing complications such as infection, hernia, fistula, adhesion, seroma, implant shrinkage and graft lost. The outer surface was also evaluated for the development of muscle tissue. The adhesion strength was evaluated and graded on the basis of consistency according to the scoring system as described in Table 1 (Jenkins et al., 1983; Tung et al., 2002; Gangwar et al., 2006).

Microscopic analysis

Light microscopy

The specimens collected from the operated area at 7th, 14th and 30th days post-implantation were fixed in 10% formalin for 24 h. The specimens were dehydrated in ascending grades of ethanol, cleared in xylene, embedded and blocked in paraffin wax and then cut into 4 µm thick sections by a rotatory microtome (Leica 2045, Germany). The sections were stained with haematoxylin and eosin for general histology and also Masson's trichrome staining for the demonstration of collagen and muscle tissues. The stained sections were examined under light microscope (Olympus BX51, Japan).

Scanning electron microscopy

Specimens were trimmed into 1 cm² blocks and fixed in 4% glutaraldehyde buffered solution 12 to 24 h at 4°C. The samples were washed three times in 0.1 M sodium cacodylate buffer at pH 7.3 for 10 min each and then post fixed for 2 h with 1% osmium tetroxide at room temperature and washed with 0.1 M sodium cacodylate buffer for 3 changes of 10 min each. The samples were dehydrated in ascending grades of acetone solution and brought to critical point drying by critical point drier (CPD 030, Bal-TEC,

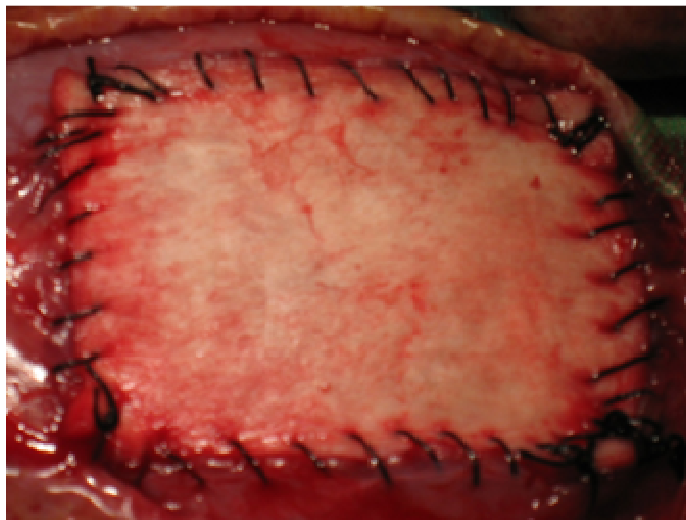


Figure 1. Photograph showing 3 x 4 cm abdominal defect repaired with the same size scaffolds stitched with a continuous suture pattern and single interrupted suture pattern at the corner.

Table 1. Scoring system for estimating the adhesion degree.

Degree	Adhesion classification
0	No adhesion
1	Minimal adhesions that could be freed by slight pull
2	Moderate adhesion that could be freed by aggressive blunt dissection
3	Strong adhesions that required sharp dissection to free

Switzerland) for about 30 min. Then, the specimens were affixed to a metal SEM aluminium stub and sputter coated in gold by using SEM coating unit (E 5100 Polaron, England). The coated specimens were viewed by scanning electron microscopic (LEO 1455 VPSEM attached with OXFORD INCA ENERGY 300 EDX, UK) at accelerating voltage of 20 to 30 kv.

Statistical analysis

Anesthesia recovery times in between groups were assessed by using independent sample t-test. Mann-Whitney U-test was used to compare adhesion formation and score between treatment and control groups. $P < 0.05$ was considered to be significant.

RESULTS

Macroscopic analysis

Clinically, none of the animal died during the surgical procedure and no post-implantation mortality was recorded. The operated rabbits repaired by bovine pericardium and tunica vaginalis scaffolds were recovered from anesthesia smoothly within 46.56 ± 4.69 and 45.44 ± 4.83 min (Mean \pm SE), respectively and no significant differences ($P > 0.05$) were obtained between mean of

the two groups. However, the rabbits in both groups appeared dull, depressed and partially anorectic for 1 to 2 days of early stage post-operation. Food and water intake normalized by 2nd to 3th post-operative day. The surgical wounds appeared healthy throughout the period of observation in both groups.

Macroscopically, the implant were well tolerated by the recipient animals, with no episodes of rejection, infection, seroma, sign of herniation and also neither pericardium nor tunica vaginalis group showed fluid leakage through the implanted scaffolds. The host-graft junctions were clearly filled with white fibrous tissue, firmer and intact in both groups (Figure 2).

The newly developed white fibrous connective tissue, adipose tissue and neo-peritoneum, later was accompanied with numerous fine new blood vessels mainly capillaries in both groups; the peritoneal surface appeared relatively irregular as a result of excess accumulation of fibrous tissue (Figure 3). At day 30th of post-implantation, the peritoneal surfaces of the implanted grafts were completely covered by newly formed peritoneum with few blood vessels (Figure 4) and adipose tissue, which was not sufficient to bear the weight and pressure of abdominal viscera especially in bovine pericardium scaffolds. Despite pouching and distension

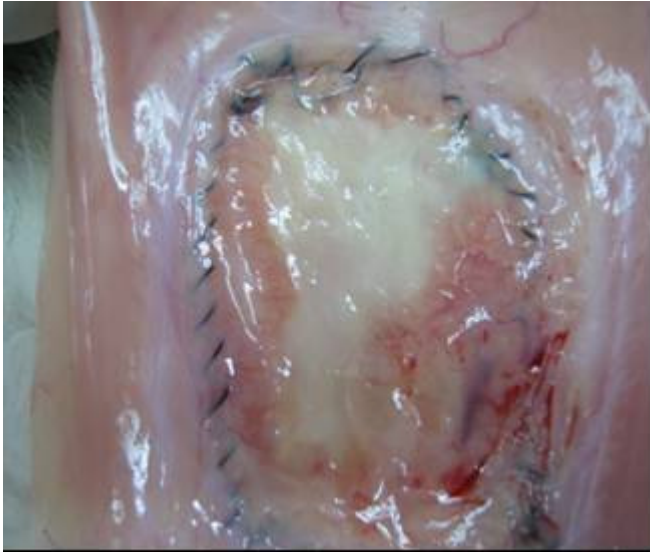

Figure 2. Photograph of the implanted bovine pericardium at day 14 post-implantation shows newly form peritoneum migrating from the surrounding towards the centre with fatty tissue at the centre, sprouting blood vessels and white fibrous tissue at host-graft junction of the peritoneal surface.

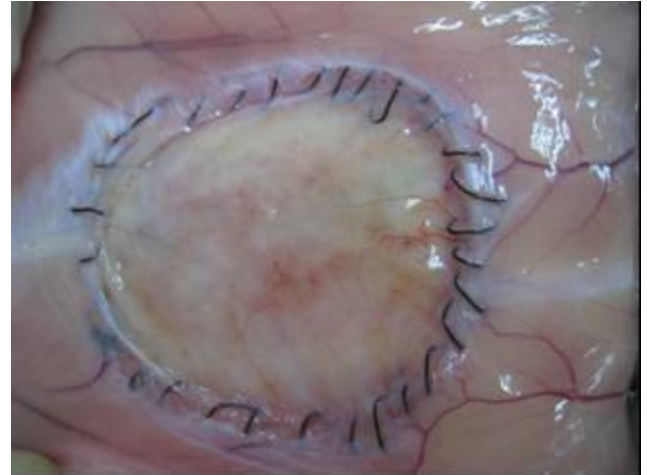

Figure 4. Photograph of the implanted tunica vaginalis parietalis at day 30 of post-implantation shows that, the implant is well integrated with the host tissue.

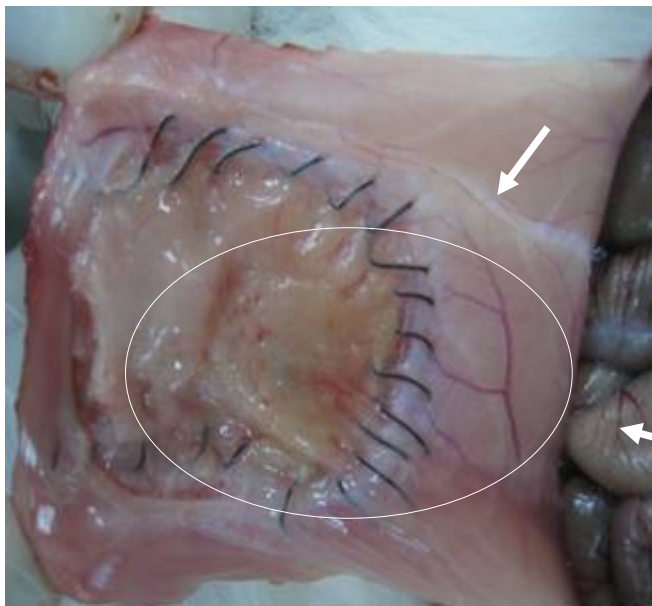


Figure 3. Photograph of the implanted bovine tunica vaginalis parietalis at day 14 post-implantation shows whitish appearance of the fibrous tissue at host-graft junction and excess accumulation of connective tissue and adipose tissue at the construct site of the peritoneal surface (circle).

appearance (Figure 5), none of the groups showed hernia at day 30th of post-implantation. Adhesions scoring in both groups are shown in Table 2. Group I, showed a single minor region of adhesion at each 7th, 14th and 30th day of post-implantation. However, in group II moderate

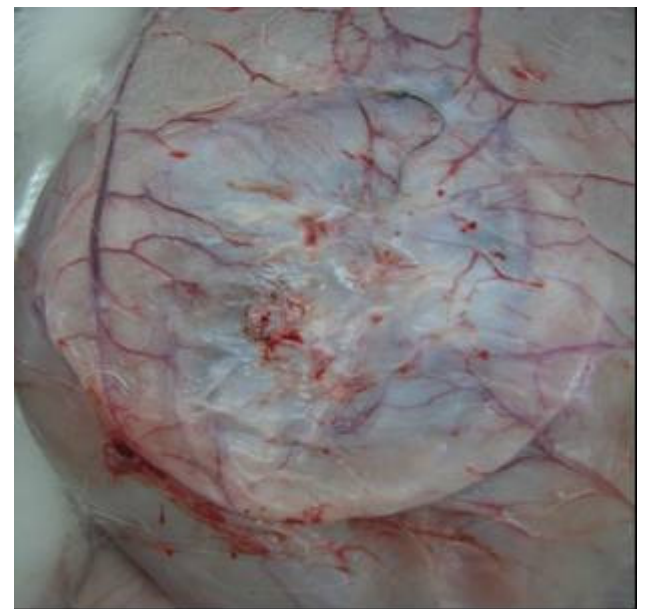


Figure 5. Photograph of the subcutaneous surface of the implanted bovine pericardium at day 30 post-implantation showing a pouching structure on the abdomen.

region of adhesion was recorded only at 7th and 14th day of post-implantation (Figure 6). Interestingly, caecum was the only organ found to adhere with the implanted tissue.

Microscopic analysis

Light microscopy

Histological analysis of the implant at day 7 post-

Table 2. Scoring of adhesion formation at 7th, 14th and 30th days post implantation.

Adhesion degree	Euthanizing date					
	Day 7 th		Day 14 th		Day 30 th	
	BP	BTV	BP	BTV	BP	BTV
0	2	2	2	2	2	3
1	1*	1*	1*	1*	1*	0
2	0	0	0	0	0	0
3	0	0	0	0	0	0

BP, Bovine pericardium scaffold; BTV, bovine tunica vaginalis parietalis scaffold; 1*, showing minimal/minor adhesion observed between the implanted and the underlying visceral organ in a single animal.

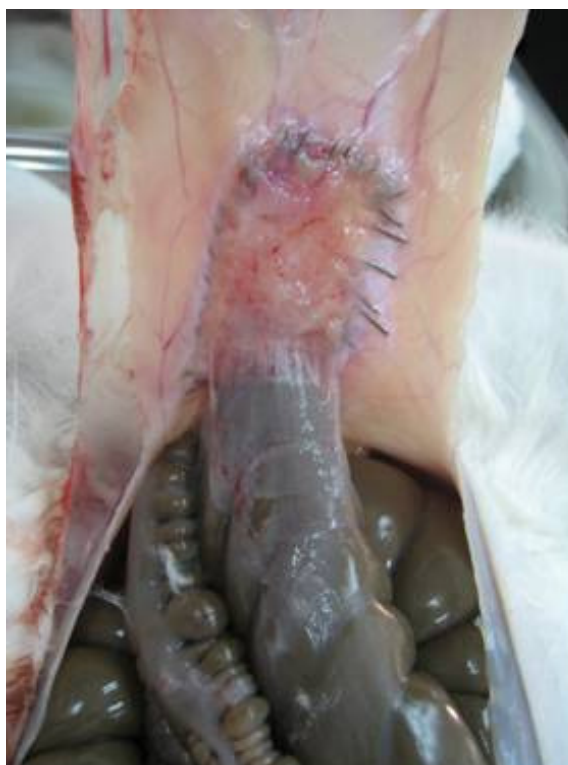

Figure 6. Photograph of the peritoneal surface at day 14 post-implantation shows moderate type of adhesion between the implant bovine tunica vaginalis parietalis and the caecum.

implantation revealed intense fibro-cellular reaction along with infiltrations of inflammatory cells particularly neutrophils, lymphocytes and macrophages with some fibroblasts and newly formed capillary vessels in both groups (Figure 7). At day 14 post-implantation, there was a marked presence of fibroblasts, collagen fibers with neovascularisation (Figure 8). At day 30 of post-implantation, the implant seems resorbed completely in the case of bovine pericardium but not fully resorbed in bovine tunica vaginalis with a narrow presence of

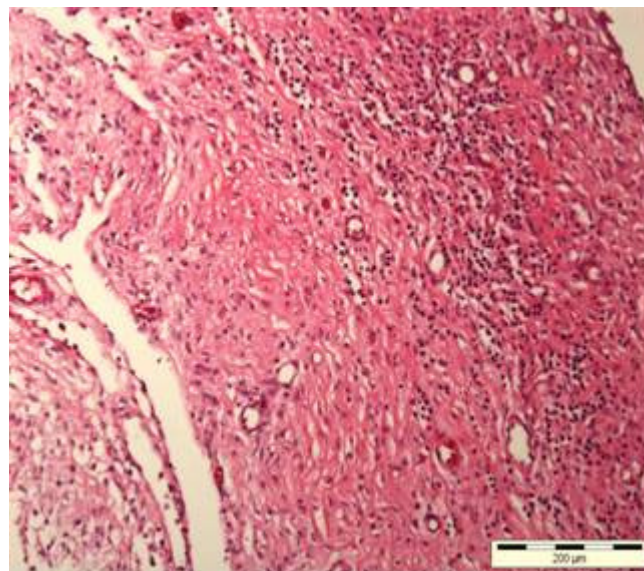


Figure 7. Microphotograph showing the inflammatory cells dispersed on the implanted scaffold on 7th day post-implantation. H and E stain.

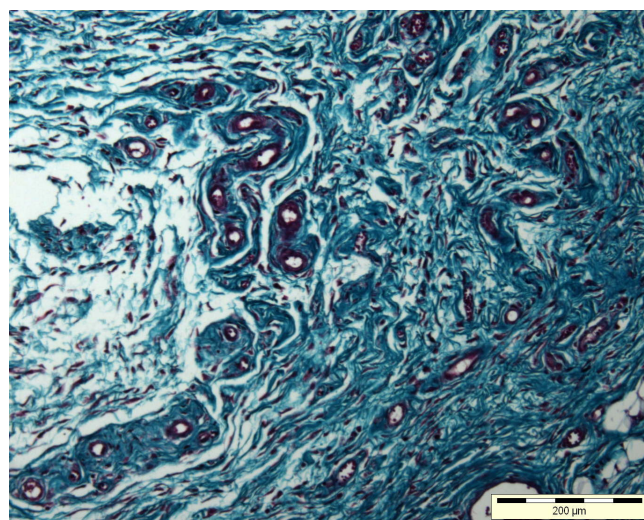


Figure 8. Microphotograph showing green color collagen fiber replaces the implanted scaffold with neo-vascularization on the 14th day of post-implantation. Masson trichrome stain.

inflammatory cells and overwhelming of newly formed blood vessels. Most interestingly, the inflammatory reaction was decreased drastically with the advance of post-operation time and no foreign body giant cells were detected throughout the study in both groups.

Scanning electron microscopy (SEM)

The SEM electromicrographs of the prepared bovine pericardium and tunica vaginalis scaffolds exhibited the

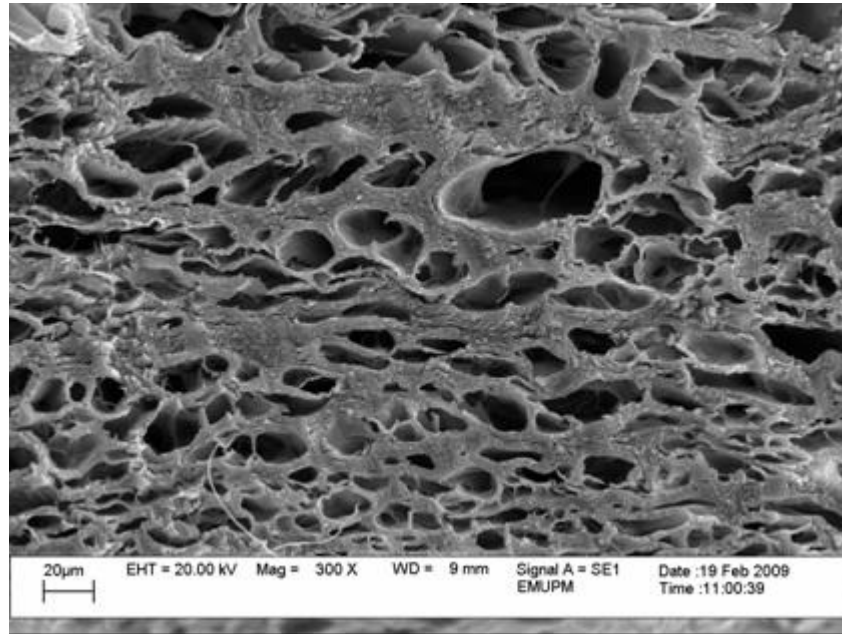


Figure 9. SEM electronmicrograph of the cross sectioned scaffold of bovine pericardium before implantation showing good porosity.




Figure 10. SEM electronmicrograph of the cross sectioned scaffold of bovine tunica vaginalis parietalis before implantation showing good porosity.

desired interconnected structure with sufficient porosity in a cross sectioned (Figures 9 and 10). Peritonization was detected at the early stage. However, well organized mesotheliazation with polygonal shapes of cells covering the peritoneal surfaces were observed at 30th days of post-implantation (Figure 11).

DISCUSSION

Biomaterials provide mechanical stability to the construct in the short term and serve as a template for the three-dimensional organization for the developing tissue (Hutmacher et al., 2001). Lack of strength over time is a

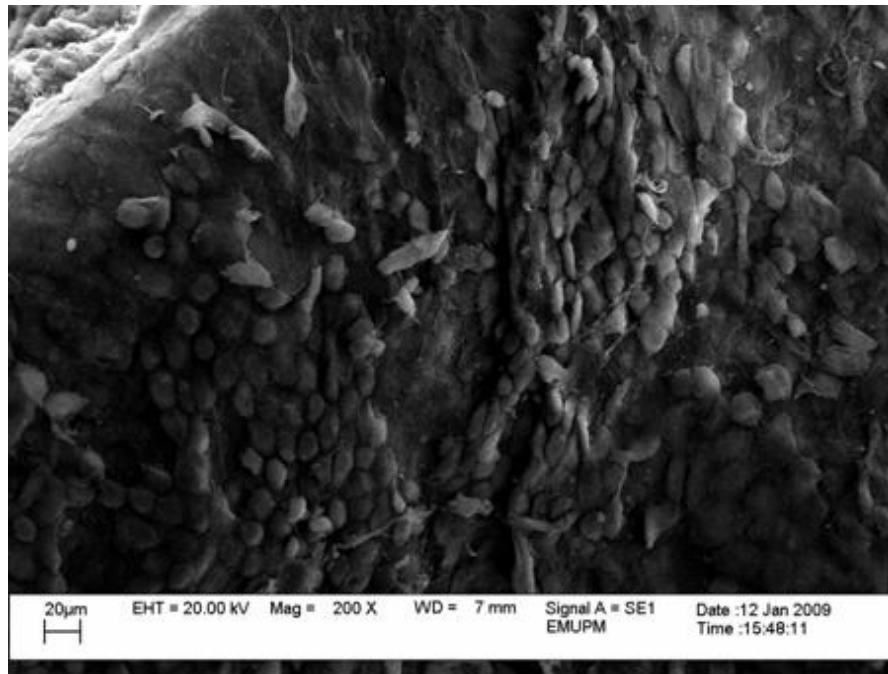


Figure 11. SEM electronmicrograph of the peritoneal surface of bovine tunica vaginalis parietalis mesotheliazation with polygonal shape of mesothelial cells on 30th day of post-implantation.

concern for clinical applications in which adequate tensile properties are necessary. For this reason, it is essential to understand the biological response and also the expected mechanical properties of the implant and replacement tissue over time. Recently, several kinds of naturally derived biomaterials scaffolds, such as porcine small intestinal submucosa (Badylak et al., 2002), acellular dermal matrix (Chung et al., 2003) and human dura mater (Takahashi et al., 1994) have been employed to repair abdominal wall defects in experimental animal models. It is therefore, necessary to select carefully the most appropriate biomaterial to avoid post-implant complications including the appearance of adhesions formation, intestinal fistulas or even migration of the biomaterial to hollow organs (Chew et al., 2000).

Clinically, neither during surgical process nor post-implantation mortality was recorded, which may be due to satisfactory anaesthetic techniques and thereby, leading the animal to tolerate well to the surgical procedure. Dullness, depression and partial anorexia in the immediate postoperative period was attributed to surgical trauma and inflammation at the site of reconstruction (Chung et al., 2003).

Macroscopically, none of the groups showed infection or seroma. However, at 30th day post-implantation, bovine pericardium showed thinning and fascial weakness which was evidenced by pouching and distension appearance of the abdominal wall. Report had proven that, scaffolds covered with cells had better mechanical properties than acellular scaffolds as shown in body wall repair using

small intestinal submucosa seeded with cells (Lai et al., 2003). Moreover, acellular collagen-based matrix alone may be insufficient scaffold for abdominal wall reconstruction (Fauza et al., 2001). 33 and 22% of mild types of adhesion were recorded in bovine pericardium and tunica vaginalis, respectively, which could be explained by the delay of mesotheliazation. However, our data suggests that there was no significant difference between groups in adhesion formation.

Microscopically, the inflammatory response in both groups of animal was intense at 7th days post-implantation. It was indeed an immediate response initiated by surgical trauma when the abdominal wall defects were created which perhaps correlated with the inflammatory phase of defects. A similar observation was reported by many researchers (Gamba et al., 2002; Gangwar et al., 2006; Singh et al., 2008). Another important finding was gradual reduction of inflammation in every advancing period post-operation. A possible explanation for this might be that, of the processing method to produce fibrocollagenous scaffolds is better to remove antigenic proteins and maintain graft integrity. It might also be associated with early degradation and resorption of the implant. In addition, absences of foreign body giant cells were noticed in both groups. This could suggest the biocompatibility of the scaffolds with the host tissue. The vascular change at reconstructive site is a part of normal body response to injury. It is an attempt to increase resorption and removal of clot and debris from the wound site and finally, helping in the laying down of fibrous

tissue (Silver, 1982). Bovine tunica vaginalis were not completely resorbed at 30th day of post-implantation, which might be attributed to its higher density of fibro-collagenous nature than bovine pericardium originated scaffolds. One unanticipated finding was that, no sign of host muscle-cell migration or lack of skeletal muscle tissue development in the constructed area despite its importance for abdominal wall. Electromicrographs showed that, adequate porosity with interconnected pores is found in both types of scaffolds which consequently, help to achieve sufficient cell seeding density within the scaffold and also, facilitate cell proliferation and differentiation by allowing the transport of nutrients and oxygen into and out of the scaffold (Goddard and Hotchkiss, 2007).

Conclusion

The present finding demonstrates that, both lyophilized bovine pericardium and tunica vaginalis can be used for reconstruction of large abdominal wall defects. However, further research needs to be done on regeneration of skeletal muscle tissue using tissue engineering technology.

ACKNOWLEDGEMENTS

The authors wish to thank Dr. Awang Hazmi, Dr. Nurul Huda, Dr. Kamran Kaveh, Dr. Mazlina Mazlan, Dr. Syahar Amir, Dr. Ayalew Birhanu, Dr. Azlan Che Mat, Dr. Norhariani and Dr. Zerihun Hailemariam for their contribution during surgery. The study was supported by e-Science research grant (project no. 06-01-04-SF0203) provided by Malaysian Government.

REFERENCES

- Amid KP (1997). Classification of biomaterials and their related complications in abdominal wall hernia surgery. *Hernia*, 1: p. 1521.
- Badylak S, Kokini K, Tullius B, Simmons-Byrd A, Morff R (2002). Morphologic study of small intestinal submucosa as a body wall repair device. *J. Surg. Res.* 103: 190-202.
- Chew DK, Choi LH, Rogers AM (2000). Enterocutaneous fistula 14 years after prosthetic mesh repair of a ventral incisional hernia: a life-long risk. *Surg.* 127: 352-353.
- Chung S, Hazen A, Levine JP, Baux G, Olivier WA, Yee HT (2003). Vascularized acellular dermal matrix island flaps for the repair of abdominal muscle defects. *Plast. Reconstr. Surg.* 111: 225-232.
- Cornu O, Banse X, Docquire PL, Luyckx S, Delloye CH (2000). Effect of freeze drying and gamma irradiation on the mechanical properties of human cancellous bone. *J. Orthopaed. Res.* 18: 426-430.
- Decurtins M, Buchman P (1982). Bovine pericardium-A new graft material for hernia repair. *Res. Exp. Med.* 180:11-14.
- Fauza DO, Marler JJ, Koka R, Forse RA, Mayer JE, Vacanti JP (2001). Fetal tissue engineering: diaphragmatic replacement. *J. Pediatr. Surg.* 36: 146-151.
- Franks F (1998). Freeze-drying of byproducts putting principles into practice. *Eur. J. Pharm. Biopharm.* 45: 221-29.
- Gamba PG, Conconi MT, Piccolo RL, Zara G, Spinazzi R, Parnigotto PP (2002). Experimental abdominal wall defect repaired with acellular matrix. *J. Pediatr. Surg.* 18: 327-331.
- Gangwar AK, Sharma AK, Kumar N, Kumar N, Maiti SK, Gupta OP, Goswami TK, Singh R (2006). Acellular dermal graft for repair of abdominal wall defects in rabbits. *J. S. Afr. Vet. Ass.* 77: 79-85.
- Goddard JM, Hotchkiss JH (2007). Polymer surface modification for the attachment of bioactive compounds. *Prog. Polym. Sci.* 32: 698-725.
- Hafeez YM, Zuki ABZ, Norimah Y, Asnah H, Loqman MY, Noordin MM, Ainul-Yuzairi MY (2005). Effect of freeze-drying and gamma irradiation on biomechanical properties of Bovine Pericardium. *Cell Tissue Banking*, 6: 85-89.
- Hutmacher DW (2001). Scaffold design and fabrication technologies for engineering tissues-state of the art and future perspectives. *J. Biomater. Sci. Polym.* 12:107-24.
- James NL, Poole-Warren LA, Schindhlem BK, Mitchell RM, Mitchell RE, Howlett CR (1991). Comparative evaluation of treated BP as a xenograft for hernia repair. *Biomaterials*, 12: 801-809.
- Jenkins SD, Klamer TW, Parteka JJ, Condon RE (1983). A comparison of prosthetic materials used to repair abdominal wall defects. *Surg.* 94: 392-98.
- Lai JY, Chang PY, Lin JN (2003). Body wall repair using small intestinal submucosa seeded with cells. *J. Pediatr. Surg.* 38: 1752-55.
- Park JB, Bronzino JD (2003). *Biomaterials: Principle and Applications*. 1st ed. CRC Press LLC, New York, pp. 207-219.
- She D (2006). *Introduction to Biomaterials*, 1st ed. Tsinghua University Press and World Scientific Publishing Co. Pte. Ltd. pp. 141-253.
- Silver IA (1982). Basic physiology of wound healing in horse. *Equine Vet. J.* 14: 7-15.
- Singh J, Kumar N, Sharma AK, Maiti SK, Goswami TK, Sharma AK (2008). Acellular biomaterials of porcine origin for the reconstruction of abdominal wall defects in rabbits. *Trends Biomater. Artif. Organs*, 22: 0-0.
- Takahashi M, Ono K, Wakakuwa R, Sato O, Tsuchiya Y, Kamyu G, Nitta K, Tajima K, Wada K (1994). Use of human *dura mater* allograft for the repair of a contaminated abdominal wall defect. *Surg. Today*, 24: 468-472.
- Tung WS, Zainol J, Pilly AG, Yusof N, Yusof LM (2002). Processed bovine tunica vaginalis as a biomaterial for the repair of large abdominal wall defects in surgical treatment. *Science*, 2: 7-11.